

Diagnosis and Treatment of Autoimmune Hepatitis

Albert J. Czaja¹ and Deborah K. Freese^{1,2}

Preamble

These guidelines provide a data-supported approach to the diagnosis and management of patients with autoimmune hepatitis. They are based on the following: (1) a formal review and analysis of the published world literature on autoimmune hepatitis (914 articles) (Medline Search from 1966-2002; the search term was autoimmune hepatitis); (2) recommendations developed and published by the International Autoimmune Hepatitis Group; (3) concepts developed at the AASLD Single Topic Conference on autoimmune hepatitis in September 1999; and (4) 40 years of combined experience by both authors in the clinical and laboratory investigation and care for patients with this disease. The guidelines, intended for use by physicians, are meant to be flexible, in contrast to "standards of care," which are inflexible policies to be followed in almost every case. They have been developed in a manner consistent with the American Association for the Study of Liver Diseases' Policy Statement on Development and Use of Practice Guidelines.

Specific recommendations are based on relevant published information. In an attempt to standardize recommendations, the Practice Guidelines Committee of the American Association for the Study of Liver Diseases modified the categories of the Infectious Diseases Society of America's Quality Standards. These categories are reported with each recommendation, using the Roman numerals I through IV to determine the quality of evidence upon which the recommendations are based. The categories are as follows: I, evidence from multiple well-designed randomized controlled trials, each involving a number of participants to be of sufficient statistical power; II, evidence from at least one large, well-designed clinical trial

with or without randomization, from cohort or case-control analytic studies, or from well-designed meta-analysis; III, evidence based on clinical experience, descriptive studies, or reports of expert committees; and IV, not rated.

Background

Autoimmune hepatitis (AIH) is an unresolving inflammation of the liver of unknown cause.¹ It is characterized by the presence of interface hepatitis and portal plasma cell infiltration on histologic examination, hypergammaglobulinemia, and autoantibodies.^{1,2} Autoimmune hepatitis reflects a complex interaction between triggering factors, autoantigens, genetic predispositions, and immunoregulatory networks.^{3,4} The mean annual incidence of AIH among white Northern Europeans is 1.9 per 100,000, and its point prevalence is 16.9 per 100,000.⁵ It accounts for 2.6% of the transplantations in Europe⁶ and 5.9% in the United States.⁷ Women are affected more than men (gender ratio, 3.6:1),⁸ and all ages^{9,10} and ethnic groups¹⁰⁻¹⁴ are susceptible.

A prospective study has indicated that as many as 40% of patients with untreated severe disease die within 6 months of diagnosis.¹⁵ Cirrhosis develops in at least 40% of survivors¹⁶; 54% develop esophageal varices within 2 years after cirrhosis¹⁷; and 20% of individuals with esophageal varices die from hemorrhage.¹⁷ Sustained serum aminotransferase levels of more than 10-fold normal or more than 5-fold normal in conjunction with serum γ -globulin concentrations at least 2-fold normal identify patients with early mortality.¹⁵ Bridging necrosis or multiacinar necrosis on histologic examination progresses to cirrhosis in 82% of patients within 5 years, and mortality is 45%.¹⁸ Patients with less severe laboratory and histologic findings fare better, but cirrhosis still develops in 49% within 15 years and death from hepatic failure occurs in 10%.¹⁹ An acute onset of illness is common (40%),²⁰⁻²³ and a fulminant presentation, characterized by hepatic encephalopathy within 8 weeks of disease onset, is possible.²⁴

Three randomized, controlled treatment trials published between 1971 and 1974 have established that prednisone alone or in combination with azathioprine improves symptoms, laboratory tests, histologic findings, and immediate survival.^{15,17,25} Liver transplantation has been associated with 5-year patient and graft survivals that

Abbreviations: AIH, autoimmune hepatitis; ANA, antinuclear antibodies; SMA, smooth muscle antibodies; anti-LKM1, antibodies to liver/kidney microsome type 1; anti-ASGPR, antibodies to asialoglycoprotein receptor; anti-LC1, antibodies to liver-specific cytosol antigen type 1; anti-SLA/LP, antibodies to soluble liver antigen/liver pancreas; pANCA, perinuclear anti-neutrophil cytoplasmic antibodies; APECED, autoimmune polyendocrinopathy-candidiasis-ectodermal dystrophy.

From the ¹Divisions of Gastroenterology and Hepatology and ²Pediatric Gastroenterology and Hepatology, Mayo Clinic and Mayo Foundation, Rochester, MN.

Address reprint requests to: Albert J. Czaja, M.D., Mayo Clinic, 200 First Street S.W., Rochester, MN 55905. E-mail: czaja.albert@mayo.edu; fax: 507-284-0538. Copyright © 2002 by the American Association for the Study of Liver Diseases. 0270-9139/02/3602-0028\$35.00/0

doi:10.1053/jhep.2002.34944

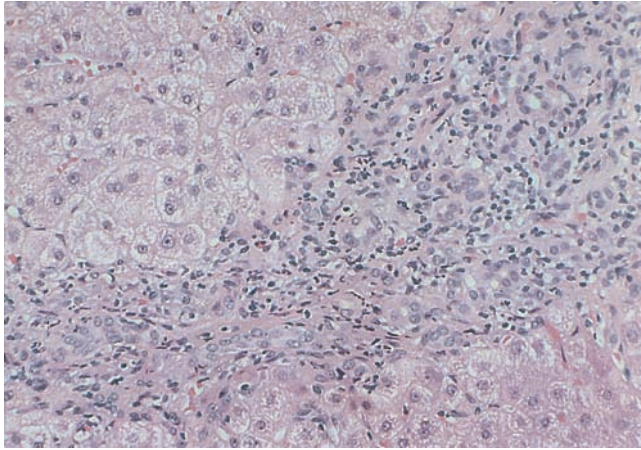


Fig. 1. Interface hepatitis. The portal tract is expanded by a mononuclear infiltrate; the limiting plate is disrupted; and the inflammatory process extends into the acinus. Staining by hematoxylin-eosin; original magnification $\times 200$.

exceed 80%,^{26,27} and recurrent disease after transplantation has been usually mild and manageable.^{6,28-35} In children, recurrence after transplantation occurs more frequently and may be more difficult to treat.³⁵

Diagnostic Criteria

Diagnosis requires the presence of characteristic features and the exclusion of other conditions that resemble AIH.^{36,37} Interface hepatitis (Fig. 1) is the histologic hallmark of the syndrome,² and portal plasma cell infiltration (Fig. 2) typifies the disorder.^{2,36-38} Neither histologic finding is disease specific, and the absence of portal plasma cells does not preclude the diagnosis. All patients suspected of AIH must be evaluated for hereditary (Wilson disease, α_1 antitrypsin deficiency, and genetic hemochromatosis), infectious (hepatitis A, B, and C infection), and drug-induced (minocycline, nitrofurantoin, isoniazid, propylthiouracil, and α -methyldopa) liver injury, some of which may have autoimmune features. The conditions most likely to be confused with AIH are Wilson disease, drug-induced hepatitis, and chronic viral hepatitis, especially chronic hepatitis C.³⁹⁻⁴¹

Liver biopsy examination is essential to establish the diagnosis and evaluate disease severity to determine the need for treatment. Serum aminotransferase and γ -globulin levels do not predict the histologic pattern of injury or the presence or absence of cirrhosis.⁴² Histologic changes, such as ductopenia or destructive cholangitis, may indicate a variant syndrome of AIH and primary sclerosing cholangitis, AIH and primary biliary cirrhosis, or autoimmune cholangitis,⁴³⁻⁴⁶ and the findings of steatosis or iron overload may suggest alternative diagnoses, such as nonalcoholic fatty liver disease, Wilson disease,

chronic hepatitis C, drug toxicity, or genetic hemochromatosis.⁴⁷ Autoantibodies must be present, and the conventional serologic markers of AIH are antinuclear antibodies (ANA), smooth muscle antibodies (SMA), and antibodies to liver/kidney microsome type 1 (anti-LKM1).^{48,49}

Diagnostic criteria have been codified and updated by an international panel (Table 1).^{36,37} Differences between a definite and probable diagnosis of AIH relate mainly to the degree of serum γ -globulin or immunoglobulin G elevation, levels of ANA, SMA, or anti-LKM1, and exposures to alcohol, medications, or infections that could cause liver injury. There is no time requirement to establish chronicity, and cholestatic clinical, laboratory, and histologic changes preclude the diagnosis. The presence of antibodies to asialoglycoprotein receptor (anti-ASGPR), liver-specific cytosol antigen type 1 (anti-LC1), soluble liver antigen/liver pancreas (anti-SLA/LP), actin (anti-actin), and/or perinuclear anti-neutrophil cytoplasmic antibodies (pANCA) support a probable diagnosis if the other conventional markers are absent.

A scoring system has been proposed to assess the strength of the diagnosis (Table 2).^{36,37} By weighing each component of the syndrome, discrepant features can be accommodated (normal serum γ -globulin level⁵⁰) and biases associated with isolated inconsistencies (destructive cholangitis⁴⁵) can be avoided. Autoimmune hepatitis typically enters remission during corticosteroid therapy and frequently relapses after drug withdrawal. These characteristic post-treatment responses have also been incorporated into the scoring system. The score based on pretreatment features can be upgraded or downgraded by the response to treatment, and inconsistent findings that

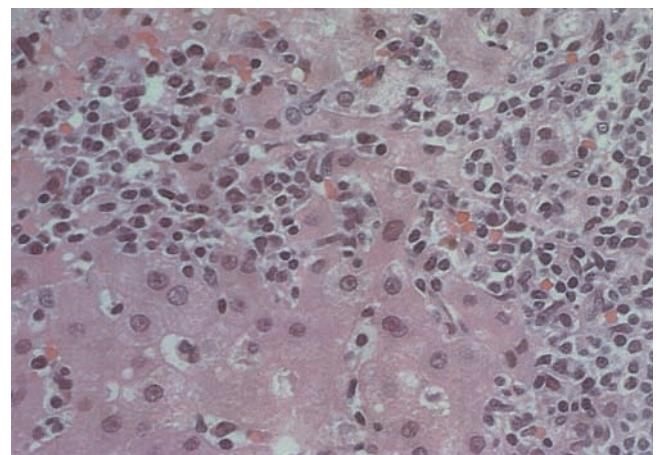


Fig. 2. Plasma cell infiltrate. Plasma cells are identified by their eccentric, clock-face nucleus and pale perinuclear cytoplasmic crescent. They are characteristic of autoimmune hepatitis, but neither pathognomonic of the disease or required for its diagnosis. Staining by hematoxylin-eosin; original magnification $\times 400$.

Table 1. Diagnostic Criteria for Autoimmune Hepatitis

Requisites	Diagnostic Criteria	
	Definite	Probable
No genetic liver disease	Normal α_1 antitrypsin phenotype Normal serum ceruloplasmin, iron, and ferritin levels	Partial α_1 antitrypsin deficiency Nonspecific serum copper, ceruloplasmin, iron, and/or ferritin abnormalities
No active viral infection	No markers of current infection with hepatitis A, B, and C viruses	No markers of current infection with hepatitis A, B, and C viruses
No toxic or alcohol injury	Daily alcohol < 25 g/d and no recent use of hepatotoxic drugs	Daily alcohol < 50 g/d and no recent use of hepatotoxic drugs
Laboratory features	Predominant serum aminotransferase abnormality Globulin, γ -globulin or immunoglobulin G level ≥ 1.5 times normal	Predominant serum aminotransferase abnormality Hypergammaglobulinemia of any degree
Autoantibodies	ANA, SMA, or anti-LKM1 $\geq 1:80$ in adults and $\geq 1:20$ in children; no AMA	ANA, SMA, or anti-LKM1 $\geq 1:40$ in adults or other autoantibodies*
Histologic findings	Interface hepatitis No biliary lesions, granulomas, or prominent changes suggestive of another disease	Interface hepatitis No biliary lesions, granulomas, or prominent changes suggestive of another disease

Abbreviation: AMA, antimitochondrial antibodies.

*Includes perinuclear anti-neutrophil cytoplasmic antibodies and the not generally available antibodies to soluble liver antigen/liver pancreas, actin, liver cytosol type 1, and asialoglycoprotein receptor.

Based on recommendations of the International Autoimmune Hepatitis Group (J Hepatol 1999;31:929-938).

Table 2. Diagnostic Scoring System for Atypical Autoimmune Hepatitis in Adults

Category	Factor	Score	Category	Factor	Score
Gender	Female	+2	Concurrent immune disease	Any nonhepatic disease of an immune nature	+2
Alk Phos:AST (or ALT) ratio	>3	-2	Other autoantibodies*	Anti-SLA/LP, actin, LC1, pANCA	+2
	<1.5	+2			
γ -globulin or IgG (times above upper limit of normal)	>2.0	+3	Histologic features	Interface hepatitis	+3
	1.5-2.0	+2		Plasma cells	+1
	1.0-1.5	+1		Rosettes	+1
	<1.0	0		None of above	-5
ANA, SMA, or anti-LKM1 titers	>1:80	+3	HLA	Biliary changes†	-3
	1:80	+2		Atypical features‡	-3
	1:40	+1		DR3 or DR4	+1
	<1:40	0			
AMA	Positive	-4	Treatment response	Remission alone	+2
				Remission with relapse	+3
Viral markers of active infection	Positive	-3			
	Negative	+3			
Hepatotoxic drugs	Yes	-4	Pretreatment score		>15
	No	+1	Definite diagnosis		10-15
Alcohol	<25 g/d	+2	Probable diagnosis		
			Posttreatment score		>17
			Definite diagnosis		12-17
	>60 g/d	-2	Probable diagnosis		

Abbreviations: Alk phos, serum alkaline phosphatase level; AST, serum aspartate aminotransferase level; ALT, serum alanine aminotransferase level; IgG, serum immunoglobulin G level; AMA, antimitochondrial antibodies; HLA, human leukocyte antigen.

*Unconventional or generally unavailable antibodies associated with liver disease include perinuclear anti-neutrophil cytoplasmic antibodies (pANCA) and antibodies to actin, soluble liver antigen/liver pancreas (anti-SLA/LP), asialoglycoprotein receptor (ASGPR), and liver cytosol type 1 (LC1).

†Includes destructive cholangitis, nondestructive cholangitis, or ductopenia.

‡Includes steatosis, iron overload consistent with genetic hemochromatosis, alcohol-induced hepatitis, viral features (ground-glass hepatocytes), or inclusions (cytomegalovirus, herpes simplex).

Based on recommendations of the International Autoimmune Hepatitis Group (J Hepatol 1999;31:929-938).

do not affect treatment response may not alter the diagnosis. The definite diagnosis prior to corticosteroid treatment requires a score greater than 15, whereas the definite diagnosis after corticosteroid treatment requires a score greater than 17 (Table 2).

The original scoring system has been validated against AIH and other chronic liver diseases. The sensitivity of the scoring system for AIH ranges from 97% to 100%,⁵⁰⁻⁵² and its specificity for excluding AIH in patients with chronic hepatitis C ranges from 66% to 92%.⁵²⁻⁵⁴ In most instances, the scoring system is unnecessary for the diagnosis of AIH since the clinical, laboratory, and histologic components of the syndrome are usually well defined.⁵⁰ The major value of the scoring system may be in the objective assessment of variant or atypical syndromes that resemble the classical disease.^{43-46,55} Its major weakness has been in excluding cholestatic syndromes with autoimmune features. Among these disorders, the ability of the scoring system to exclude AIH has ranged from 45% to 65%.^{50,55} This weakness has justified revision of the scoring system to further downgrade cholestatic findings.³⁷ Preliminary assessments of the revised system by retrospective analysis of prospectively acquired patient data have indicated a better performance in excluding biliary diseases.⁵⁶

The diagnostic criteria for children are different from those of adults.^{36,37} Autoantibody titers tend to be lower in children, and the presence of autoantibodies in any titer, in combination with other requisite elements, is sufficient to support a definite diagnosis (Table 1). Autoantibodies are neither pathogenic nor disease specific,⁴⁹ and their expression can vary during the course of AIH.⁵⁷ A single low autoantibody titer should never exclude the diagnosis of AIH in an adult or child, nor should high titers establish the diagnosis in the absence of other supportive findings. Seronegative individuals may be classified at presentation as having cryptogenic chronic hepatitis until conventional markers appear later in the course⁵⁷⁻⁵⁹ or until autoantibodies that are not generally available are tested.^{60,61} Autoantibody titers reflect the strength of the immune response, and they are useful only in diagnostic schemes to complement other features that support the diagnosis of AIH. Autoantibodies do not cause the disease nor do their levels reflect response to treatment. Accordingly, they do not need to be monitored.^{36,37,41,46}

A unique form of sclerosing cholangitis in children (sometimes termed "autoimmune sclerosing cholangitis") has been described in a single center.^{62,63} This disease may mimic classic AIH, and cholangiography is often needed to distinguish the disorders. The small number of reported cases, the lack of general agreement regarding the

nature of the process, and the absence of a treatment consequence do not compel the routine performance of cholangiography in the initial evaluation.

Conventional Repertoire of Autoantibodies

ANA, SMA, and anti-LKM1 should be determined in all patients with clinical, laboratory, and/or histologic features that suggest the diagnosis of AIH, and they constitute the conventional repertoire of autoantibodies for this condition.^{36,37}

ANA are the traditional markers of AIH, and they are present alone (13%) or with SMA (54%) in 67% of patients with the disease.⁵⁷ Nuclear reactivity can be assessed by indirect immunofluorescence on Hep-2 cell lines⁶⁴ or by an enzyme immunoassay using microtiter plates with adsorbed recombinant or highly purified antigens.⁶⁵ The nuclear targets of ANA in AIH are uncertain, and many ANA in AIH are nonreactive to the major recombinant nuclear antigens.⁶⁴ Some medical centers, therefore, prefer to assess ANA by indirect immunofluorescence until the performance parameters of enzyme immunoassay in AIH are fully defined.

ANA in AIH react against diverse recombinant nuclear antigens, including centromere, ribonucleoproteins, and ribonucleoprotein complexes.⁶⁴ None of these reactivities has been associated with a specific pattern of indirect immunofluorescence or prognostic importance.⁶⁴ Furthermore, the patterns of indirect immunofluorescence (homogenous versus speckled) have had no clinical significance.⁶⁶ ANA can be found in primary biliary cirrhosis,^{67,68} primary sclerosing cholangitis,^{69,70} chronic viral hepatitis,^{71,72} drug-related hepatitis,^{73,74} nonalcoholic steatohepatitis,^{47,75} and alcohol-induced liver disease,^{76,77} and their expression can be variable in the same patient.⁵⁷

SMA are directed against actin and nonactin components, including tubulin, vimentin, desmin, and skeleton, and they are also standard markers of AIH.^{48,49,78-80} SMA are present in 87% of patients with AIH, either as the sole marker of the disease (33%) or in conjunction with ANA (54%).⁵⁷ Three types have been described using cultured fibroblasts treated with vinblastine. These are antibodies to actin, tubulin, and intermediate filaments.⁷⁸⁻⁸⁰ SMA are present in a variety of liver and nonliver diseases, and their utility as diagnostic markers depends on the clinical syndrome.^{69-72,80} Like ANA, SMA have a variable expression in individual patients.⁵⁷ Typically, SMA are demonstrated in the clinical laboratory by indirect immunofluorescence on murine stomach and kidney.^{49,79-81}

Anti-LKM1 typically occur in the absence of SMA and ANA.^{82,83} Seropositivity requires reactivity against the proximal tubules of the murine kidney and the hepato-

cytes of the murine liver by indirect immunofluorescence.^{49,83} Antibodies-LKM1 react with high specificity to a short linear sequence of the recombinant antigen, cytochrome mono-oxygenase CYP2D6 (P450 IID6), and they also inhibit CYP2D6 activity *in vitro*.^{84,85} These findings together with evidence that liver-infiltrating lymphocytes have specific reactivity to CYP2D6 have implicated this cytochrome as an autoantigen in AIH.⁸⁶ Homologies exist between CYP2D6 and the genome of the hepatitis C virus,⁸⁴ and occasionally anti-LKM1 can be found in this infection.⁸⁷⁻⁹⁰ The absence of anti-LKM1 among patients with chronic hepatitis C in the United States⁹¹ may relate to environmental factors, host genetic predispositions, or regional differences in the viral genotype associated with anti-LKM1.^{92,93} The anti-LKM1 found in chronic hepatitis C in Europe react to different epitopes on the recombinant CYP2D6 molecule than anti-LKM1 associated with AIH, and these diverse reactivities distinguish the antibodies.^{88,94}

Antibodies to LKM1 are rare in the United States, occurring in only 4% of adults with AIH.⁸³ They have been described mainly in pediatric patients in Europe, but 20% of patients with anti-LKM1 in France and Germany are adults.⁸² The reasons for these regional differences in the occurrence of anti-LKM1 in AIH are unknown, but they may reflect variable host expression of CYP2D6, genetic differences in the immune response to the target antigen, or other host-related or region-specific factors.^{95,96} The rarity of anti-LKM1 among North American patients does not preclude testing for these markers in patients with suspected AIH who lack other autoantibodies.^{36,37,97}

pANCA are common in AIH, and their assay is generally available.⁹⁸⁻¹⁰⁰ They have been used to reclassify patients with cryptogenic chronic hepatitis as AIH,¹⁰¹ but they have not been formally assimilated into the diagnostic algorithm. pANCA do not have diagnostic specificity for AIH nor do they have prognostic implications.^{102,103}

Evolving Repertoire of Autoantibodies

New autoantibodies continue to be characterized because they may be imprints of the underlying immunopathic process and clues to an important target autoantigen. Furthermore, they may enhance diagnostic precision and/or be useful as prognostic indices. Antibodies to actin (anti-actin), ASGPR, SLA/LP, and LC1 are in this category. These markers are not generally available, and their assays have not been standardized. They are investigational in nature but of sufficient promise to support the probable diagnosis of AIH.^{36,37}

Anti-actin have greater specificity for AIH than SMA.¹⁰⁴ A thermolabile F-actin depolymerizing factor

has been described in serum, and the best assay for detection of anti-actin is unestablished.¹⁰⁵ Preliminary studies using multiple assays have indicated the occurrence of anti-actin in patients who more commonly have HLA DR3, early age onset, and poorer response to corticosteroid therapy than patients without anti-actin.⁸¹ Anti-actin may have a prognostic significance that so far has eluded conventional autoantibodies.⁸¹ They have less sensitivity for AIH than SMA, and they are unlikely to replace SMA as a diagnostic tool.⁸¹

Anti-ASGPR can coexist with ANA, SMA, and anti-LKM1, and they may also have prognostic importance.^{106,107} Anti-ASGPR are directed against a transmembrane glycoprotein on the hepatocyte surface, which can capture, internalize, and display potential antigens.¹⁰⁸ Their presence correlates with histologic activity; their disappearance connotes response to treatment; and their persistence heralds relapse after corticosteroid withdrawal.¹⁰⁹⁻¹¹¹ Anti-ASGPR may be generic markers of AIH, biological probes of an important autoantigen, and/or important indices of treatment response.

Anti-SLA/LP are highly specific markers of AIH.¹¹² A 50-kd cytosolic protein is the target autoantigen,¹¹³ and it is probably a transfer ribonucleoprotein complex (tRNA^{(Ser)Sec}) involved in the incorporation of selenocysteine in polypeptide chains¹¹⁴ or a serine hydroxymethyltransferase involved in the selenocysteine pathway.¹¹⁵ Anti-SLA/LP do not define a valid subgroup of AIH, but they do allow reclassification of patients with cryptogenic chronic hepatitis as AIH.^{60,116} Furthermore, they have been associated with HLA DR3 and a propensity for AIH to relapse after corticosteroid withdrawal.¹¹⁷ A standardized enzyme immunoassay for anti-SLA/LP has been validated by Western blot using recombinant antigen, and a commercial assay is available in Europe.^{112,116} Complementary DNA encodes for the major but not the sole antigenic component of SLA/LP, and the inclusion of a truncated form of the antigen (SLA-p35) within the assay may improve its sensitivity against native SLA/LP.¹¹⁸

Anti-LC1 are specific for AIH, and formiminotransferase cyclodeaminase^{119,120} and argininosuccinate lyase¹²¹ have been proposed as the antigenic targets. Anti-LC1 are rare in patients older than 40 years, and their prevalence is higher in populations younger than 20 years.¹²² Thirty-two percent of individuals with anti-LC1 have anti-LKM1, and in some studies, the antibodies have been associated with concurrent immunologic diseases, marked hepatocellular inflammation, absence of infection with hepatitis C virus, and rapid progression to cirrhosis.^{122,123} Recent investigations have contested the clinical importance of anti-LC1 as the antibodies have been absent in children with fulminant AIH, demonstrated in

patients with primary sclerosing cholangitis, and detected in individuals with chronic hepatitis C.¹²⁴ Serum levels fluctuate with inflammatory activity in contrast to anti-LKM1, and anti-LC1 may ultimately prove useful as markers of residual hepatocellular inflammation or as probes of an autoantigen associated with disease severity.¹²⁵

Subclassifications

Three types of AIH have been proposed based on differences in their immunoserologic markers.^{82,97,126,127} They do not have distinctive etiologies or responses to corticosteroid therapy, and the International Autoimmune Hepatitis Group has not endorsed them as valid clinical entities.^{36,37}

Type 1 AIH is the most common form of the disease worldwide, and it is associated with ANA and/or SMA.⁹⁷ It affects all age groups, and it is associated with HLA DR3 (*DRB1*0301*) and DR4 (*DRB1*0401*) in Caucasian Northern European and North American patients.^{128,129} *DRB1*0301* and *DRB1*0401* influence disease expression and behavior as well as susceptibility. Caucasian patients with type 1 AIH and *DRB1*0301* are younger,¹³⁰ and they have a higher frequency of treatment failure,¹³⁰ relapse after drug withdrawal,¹³¹ and requirement for liver transplantation^{26,27} than patients with other alleles. In contrast, patients with *DRB1*0401* are typically older, frequently have concurrent autoimmune diseases, and respond better to corticosteroids than counterparts with *DRB1*0301*.^{130,132} The strong clinical associations with HLA phenotype do not affect the diagnosis and treatment of type 1 AIH, and the class II HLA are not routinely determined.

Type 2 AIH is characterized by anti-LKM1.⁸² It is more common in Europe^{82,84} and some South American countries⁹⁶ than in the United States, and susceptibility may relate to *DRB1*0701*.^{95,96} Earlier perceptions that type 2 AIH had a poorer outcome than type 1 AIH⁸² have not been corroborated, and both types respond well to corticosteroids.⁶² pANCA, which are common in type 1 AIH, are not detectable in type 2 disease.¹⁰⁰

A distinct form of LKM-positive AIH has been recognized in association with autoimmune polyendocrinopathy-candidiasis-ectodermal dystrophy (APECED).¹³³⁻¹³⁵ APECED is due to a single gene defect on chromosome 21q22.3 which may alter thymic deletion of autoreactive T cells.¹³⁶⁻¹³⁸ It is characterized by ectodermal dystrophy, mucocutaneous candidiasis, multiple endocrine gland failure (parathyroids, adrenals, ovaries), autoantibody production, and AIH in various syndromic combinations.¹³³⁻¹³⁵ Unlike other autoimmune diseases, APECED has a Mendelian pattern of inheritance, no

HLA DR associations, and no female predominance. Patients with the APECED and AIH have a particularly aggressive liver disease that does not respond well to standard immunosuppressive regimens.¹³³⁻¹³⁵

Type 3 AIH is the least established form of the disease,⁹⁷ and it is characterized by the presence of anti-SLA/LP in serum.^{126,127} Patients have clinical and laboratory features that are indistinguishable from patients with type 1 AIH, and they respond well to corticosteroids.^{60,116}

Recommendations

1. The diagnosis of AIH requires determination of the serum aminotransferase and γ -globulin levels; detection of ANA and/or SMA, or in their absence, anti-LKM1; and liver tissue examination (Rating, III).

2. The diagnostic criteria for AIH that are defined in Table 1 should be applied to all patients (Rating, III).

3. If the diagnosis of AIH is not clear, a scoring method should be used as shown in Table 2 (Rating, II).

Treatment Indications

Three randomized, controlled trials have shown improvement in the clinical and histologic features and survival of severe AIH after corticosteroid therapy.^{15,17,25} Subsequent studies have indicated that patients with histologic cirrhosis respond as well to corticosteroid treatment as patients without cirrhosis.¹³⁹ Furthermore, the 20-year life expectancy for all treated patients exceeds 80%, and survival is similar to that of age- and sex-matched normal subjects from the same geographical region.¹³⁹

Similar treatment trials have not been performed in patients with less severe disease, and their indications for treatment remain uncertain.¹⁴⁰ Laboratory disturbances of a mild-to-moderate degree are associated with cirrhosis in 49% within 15 years and a 10-year survival of 90%.¹⁹ Untreated patients with interface hepatitis have a 17% probability of cirrhosis within 5 years and normal 5-year life expectancy.^{18,141} The benefit-risk ratio of therapy in such patients is undefined, and it may be so low that corticosteroids are unjustified. Furthermore, the patients with mild disease included in the early reports may have had chronic hepatitis C infection, which could not be detected by the available assays.¹⁴² Under such circumstances, the frequency of asymptomatic or mild AIH and its natural history may have been misrepresented.

The indications for corticosteroid treatment in patients with mild AIH must be individualized, and the symptoms, disease behavior, and potential for drug-related side effects must be balanced against each other. Clinical judgment is the principal basis for the treatment

decision. Patients likely to have a poor outcome are those at increased risk for drug intolerance, and they include individuals with advanced inactive cirrhosis, postmenopausal osteopenia or vertebral compression, emotional lability or psychosis, poorly controlled hypertension, and brittle diabetes.¹⁴³

Individuals with cirrhosis at presentation have a higher frequency of drug-related complications than those without cirrhosis (25% vs. 8%), presumably because of increased serum levels of unbound prednisolone resulting from prolonged hypoalbuminemia and/or hyperbilirubinemia.^{144,145} Similarly, patients with advanced age and/or menopause are at increased risk for osteopenia and vertebral compression.^{146,147}

Postmenopausal patients tolerate initial therapy as well as premenopausal counterparts, and their outcomes are similar.¹⁴⁸ Relapse and retreatment, however, are tolerated less well, and the frequency of vertebral compression is higher in the postmenopausal group.¹⁴⁸ Advanced age, postmenopausal status, and the presence of cirrhosis are features associated with an increased risk of drug-related complications. Each feature, however, does not contraindicate the institution of treatment, and in fact, patients with these characteristics enter remission as commonly as others with disease of similar severity.^{140,148-150} The risk of side effects compels careful selection of patients for therapy, and the institution of regular follow-up examinations.

Pregnancy or the contemplation of pregnancy does not contraindicate immunosuppressive therapy.¹⁵¹⁻¹⁵³ Expectant mothers typically respond as well to treatment as others, and there have been only theoretical concerns regarding teratogenicity associated with azathioprine treatment.¹⁵⁴ Skeletal anomalies, cleft palate, reduction in thymic size, hydrops fetalis, anemia, and hematopoietic suppression have been described in mice treated experimentally with higher than pharmacologic doses of azathioprine.¹⁵⁴ These laboratory observations have not been reflected in the human experience, but the use of prednisone alone during pregnancy eliminates any concern.

Pregnant women with AIH have a higher than normal frequency of prematurity, low birth weights, and fetal loss.^{151,152} These women typically tolerate pregnancy satisfactorily unless their disease is advanced and complicated by ascites and esophageal varices. Under such circumstances, the risk of variceal hemorrhage may be increased.¹⁵⁵ Patients with advanced liver disease and portal hypertension are commonly amenorrheic and/or infertile, and pregnancy is uncommon. Effective contraception should be advised in those rare, actively menstruating women with advanced liver disease.¹⁵⁵

Table 3. Indications for Treatment

Absolute	Relative
Serum AST \geq 10-fold upper limit of normal	Symptoms (fatigue, arthralgia, jaundice)
Serum AST \geq 5-fold upper limit of normal and γ -globulin level \geq twice normal	Serum AST and/or γ -globulin less than absolute criteria
Bridging necrosis or multiacinar necrosis on histologic examination	Interface hepatitis

Abbreviation: AST, serum aspartate aminotransferase level.

The indications for treatment in children are similar to those in adults. The disease process in children appears to be more severe at presentation than commonly seen in adults, perhaps because of delays in diagnosis.^{62,63,156-158} Over 50% of children have cirrhosis at accession, and the milder forms of the disease described in adults are not typically seen in children.^{62,63,156-158} The perceived aggressive course in most children and reports that delays in diagnosis and treatment adversely affect the long-term outcome have justified drug therapy at the time of diagnosis.^{62,63,156-158} Only those children with advanced cirrhosis without evidence of inflammatory activity are unlikely to benefit.

The indications for treatment are shown in Table 3.

Recommendations

1. Treatment should be instituted in patients with serum aminotransferase levels greater than 10-fold the upper limit of normal (Rating, I).
2. Patients with serum aminotransferase levels that are 5-fold the upper limit of normal in conjunction with a serum γ -globulin level at least twice the upper limit of normal should be treated (Rating, I).
3. Histologic features of bridging necrosis or multiacinar necrosis compel therapy (Rating, I).
4. Patients not satisfying the criteria in recommendations 1 through 3 must be individualized and treatment should be based on clinical judgment. The presence of interface hepatitis without bridging necrosis or multiacinar necrosis on histologic examination does not compel treatment (Rating, III).
5. Treatment may not be indicated in patients with inactive cirrhosis, preexistent comorbid conditions, or drug intolerances (Rating, III).
6. Treatment is warranted in most children at the time of diagnosis (Rating, II).

Treatment Regimens

Two treatment regimens are comparable with each other and superior to nonsteroidal therapies in the management of severe AIH in adults (Table 4).¹⁴³ Prednisone alone or a lower dose of prednisone in conjunction with

Table 4. Treatment Regimens for Adults

	Prednisone Only (mg/d)	Combination	
		Prednisone (mg/d)	Azathioprine (mg/d)
Week 1	60	30	50
Week 2	40	20	50
Week 3	30	15	50
Week 4	30	15	50
Maintenance until end point	20	10	50
Reasons for Preference	Cytopenia Thiopurine methyltransferase deficiency Pregnancy Malignancy Short course (≤ 6 mo)	Postmenopausal state Osteoporosis Brittle diabetes Obesity Acne Emotional lability Hypertension	

azathioprine induces clinical, laboratory, and histologic remission with similar frequency. The combination regimen is associated with a lower occurrence of corticosteroid-related side effects than the higher dose prednisone regimen (10% vs. 44%), and it is the preferred treatment.¹⁴³ Advanced cirrhosis can significantly impair the conversion of prednisone to prednisolone, but this impairment is insufficient to alter treatment response or justify the preferential administration of prednisolone.¹⁵⁹

Eighty percent of patients develop cosmetic changes, including facial rounding, acne, dorsal hump formation, and/or truncal obesity, after two years of corticosteroid therapy.¹⁴³ Severe, potentially debilitating complications, such as osteoporosis, vertebral compression, diabetes, cataracts, hypertension, and psychosis, usually develop only after 18 months of continuous therapy and at doses of prednisone that exceed 10 mg daily.¹⁴³ Only 13% of treated patients develop complications during therapy that necessitate dose reduction or premature drug withdrawal. The most common reasons for treatment withdrawal are intolerable cosmetic changes or obesity (47%), osteopenia with vertebral compression (27%), and brittle diabetes (20%).¹⁵⁰

Complications of azathioprine include cholestatic hepatitis,¹⁶⁰ veno-occlusive disease,^{161,162} pancreatitis,^{163,164} nausea,¹⁴³ emesis,¹⁴³ rash,¹⁴³ and bone marrow suppression.^{165,166} Side effects develop in fewer than 10% of patients receiving 50 mg daily of azathioprine, and they can be improved by reduction of the dose or discontinuation of the drug.¹⁴³

Thiopurine methyltransferase mediates elimination of 6-mercaptopurine, and variations in enzyme activity can affect therapeutic action and drug toxicities.¹⁶⁷ The genes encoding thiopurine methyltransferase are highly polymorphic, and enzyme activity is inducible by azathioprine.^{167,168} Low enzyme activity is rare and estimated to

involve only 0.3% of the population. Heterozygotes with intermediate activity of thiopurine methyltransferase are more common and constitute 11% of the population.¹⁶⁷ There are no data that establish the role of routine testing for thiopurine methyltransferase in AIH, but recommendations have emerged that dissuade the use of azathioprine in individuals with low enzyme activity and the avoidance of high-dose regimens in those with intermediate levels of activity.¹⁶⁹ Pretreatment testing for thiopurine methyltransferase activity is a reasonable clinical precaution, and it should be considered in all patients, especially those with pretreatment cytopenia.

The long-term complications of immunosuppressive therapy include the theoretical possibility of oncogenicity.^{170,171} The frequency of extrahepatic malignancy is 5% in patients with a cumulative treatment duration of 42 months.¹⁷² The incidence of extrahepatic malignancy is 1 per 194 patient-years of surveillance, and the probability of tumor occurrence is 3% after 10 years. The risk of malignancy is 1.4-fold that of an age- and sex-matched normal population (range, 0.6 to 2.9), and no specific cell type predominates.¹⁷²

The risk of primary hepatocellular cancer is related mainly to the presence of cirrhosis.^{173,174} It is rare in treated patients who do not have hepatitis B and C viruses.^{174,175} In a prospective study based on annual assessments of serum α -fetoprotein level and hepatic ultrasonography, only one patient (0.5%) developed primary hepatic malignancy in 1,732 patient-years of observation, and only one of 88 patients with cirrhosis (1%) developed malignancy during 1,002 patient-years after cirrhosis (mean observation interval after cirrhosis, 10 ± 1 years).¹⁷⁴

Prednisone is appropriate as the sole medication in individuals with severe cytopenia,^{165,166} those undergoing a short treatment trial (duration of therapy, < 6 months),¹⁴³ individuals who are pregnant or contemplating pregnancy,¹⁵¹ patients with active malignancy,¹⁷⁰ and individuals with thiopurine methyltransferase deficiency (Table 4).^{165,166,169} The combination regimen is appropriate in patients who will be treated continuously for at least 6 months or who are at increased risk for drug-related complications, including postmenopausal women and individuals with emotional instability,^{143,147,148} osteoporosis, brittle diabetes, labile hypertension, and/or exogenous obesity (Table 4).^{143,146,148} Patients receiving prednisone should undergo eye examinations for cataracts and glaucoma periodically during treatment, and those receiving azathioprine in any dose should be monitored for leukopenia and thrombocytopenia.

Adjunctive therapies should be based on an awareness of possible complications of the medication, and they

Table 5. Treatment Regimens for Children

Initial Regimen	Maintenance Regimen	End Point
Prednisone, 2 mg/kg daily (up to 60 mg/d), for 2 weeks either alone or in combination with azathioprine, 1-2 mg/kg daily	Prednisone taper over 6-8 weeks to 0.1-0.2 mg/kg daily or 5 mg daily Azathioprine at constant dose if added initially Continue daily prednisone dose with or without azathioprine or switch to alternate day prednisone dose adjusted to response with or without azathioprine	Normal liver tests for 1-2 years during treatment No flare during entire interval Liver biopsy examination discloses no inflammation

should be introduced as appropriate to the individual's perceived risk. Such therapies might include a regular exercise program, vitamin D and calcium supplementation, estrogen replacement, and the administration of bisphosphonates.¹⁷⁶⁻¹⁷⁸ Asymptomatic patients on long-term corticosteroid treatment should be monitored for bone disease by annual bone mineral densitometry of the lumbar spine and hip.¹⁴⁶

Treatment regimens have been less rigorously established in children than in adults and to some extent, they reflect the preferences of individual centers.^{62,63,156-158,179} There have been no randomized, controlled treatment trials in children with AIH, but several reports of 17 or more children have documented the efficacy of regimens similar to those used in adults (Table 5).^{62,63,156-158,179} Despite the severe disease at presentation, the response to treatment with corticosteroids with or without azathioprine is generally excellent in children. Normalization of liver tests is noted after 6 to 9 months of therapy in 75% to 90%.

Prednisone is the mainstay in virtually all reported regimens for children, and it is usually administered initially in a dose of 2 mg/kg daily (up to 60 mg daily) (Table 5).^{62,63,156-158,179} Tapering schedules vary widely. In some centers, a rapid switch to alternate day regimens has been advocated, whereas in other centers, maintenance of a daily schedule is considered essential. Because of the significant deleterious effects of long-term intermediate or high-dose corticosteroid therapy on linear growth, bone development, and physical appearance, early use of azathioprine or 6-mercaptopurine for all children without contraindications is usually recommended.^{62,63,156-158,179} Experience with azathioprine alone as maintenance therapy has been limited in children, but the drug appears to hold some promise for those who do not tolerate complete cessation of treatment. Regimens incorporating cyclosporin A as initial treatment for children with AIH do not appear to confer a significant advantage over more traditional therapies, and they should be considered investigational.¹⁸⁰⁻¹⁸²

Recommendations

1. Prednisone in combination with azathioprine or a higher dose of prednisone alone is the appropriate treatment for severe AIH in adults (Rating, I).
2. Prednisone in combination with azathioprine is the preferred initial treatment because of its lower frequency of side effects (Rating, II).
3. All patients treated with prednisone alone or in combination with azathioprine must be monitored for the development of drug-related side effects (Rating, III).
4. Azathioprine or 6-mercaptopurine is preferred as a corticosteroid-sparing agent in children, especially when high doses of prednisone are required for disease control (Rating, III).

Treatment End Points

Conventional therapy in adults is continued until remission, treatment failure, incomplete response, or drug toxicity (Table 6).^{15,143} There is no prescribed minimum or maximum duration of treatment. All adult patients should be given the opportunity to enter a sustained remission by discontinuing medication after clinical, laboratory, and histologic resolution.^{150,183,184} Therapy should not be instituted with the intention of being indefinite.¹⁸⁴ Ninety percent of adults have improvements in the serum aminotransferase, bilirubin, and γ -globulin levels within 2 weeks.¹⁸⁵ Adults rarely achieve remission in less than 12 months, and the probability of remission during therapy diminishes after 2 years.^{15,20,150,183,184,186} Histologic improvement lags behind clinical and laboratory improvement by 3 to 6 months, and treatment should be continued for at least this period.^{15,42}

Remission connotes disappearance of symptoms, improvement of serum aminotransferase levels to less than twice normal, restoration of serum bilirubin and γ -globulin levels to normal, and improvement of the liver tissue to normal, portal hepatitis, or cirrhosis with minimal or no activity (Table 6).^{15,150,183,184,186} Sixty-five percent of patients enter remission within 18 months, and 80%

Table 6. End Points of Initial Treatment and Courses of Action

Treatment End Point	Criteria	Courses of Action
Remission	Disappearance of symptoms Normal serum bilirubin and γ -globulin levels Serum aminotransferase level normal or less than twice normal Normal hepatic tissue or minimal inflammation and no interface hepatitis	Gradual withdrawal of prednisone over 6-week period Discontinuation of azathioprine Regular monitoring for relapse
Treatment failure	Worsening clinical, laboratory, and histologic features despite compliance with therapy Increase of serum aminotransferase by 67% Development of jaundice, ascites, or hepatic encephalopathy	Prednisone, 60 mg daily, or prednisone, 30 mg daily, and azathioprine, 150 mg daily, for at least one month Reduction of dose each month of improvement until standard maintenance levels
Incomplete response	Some or no improvement in clinical, laboratory, and histologic features during therapy Failure to achieve remission after 3 years No worsening of condition	Reduction in doses of medication to lowest levels possible to prevent worsening Indefinite treatment
Drug toxicity	Development of intolerable cosmetic changes, symptomatic osteopenia, emotional instability, poorly controlled hypertension, brittle diabetes or progressive cytopenia	Reduction in dose or discontinuation of offending drug depending on severity of side effect Maintenance on tolerated drug in adjusted dose

achieve remission within 3 years (mean duration of treatment to remission, 22 months).^{15,20,150} Daily maintenance doses of medication should remain fixed in adults until remission is achieved (Table 4). Titrations in dose are associated with delayed or incomplete histologic improvement, and it can prolong the durations of therapy.¹⁴³ Alternate day schedules of prednisone can induce symptomatic and laboratory improvement, but nonsteroidal or placebo therapies are as effective in achieving histologic resolution.¹⁴³

Liver biopsy assessment prior to termination of treatment is preferred, but not essential, in the management of patients who satisfy clinical and laboratory criteria for remission.^{15,150} Interface hepatitis is found in 55% of patients with normal serum aminotransferase and γ -globulin levels during therapy,⁴² and these individuals invariably relapse after cessation of treatment.¹⁵⁰ Their recognition by liver biopsy examination prior to drug withdrawal can extend treatment and limit this consequence.¹⁵⁰

Relapse connotes recrudescence of disease activity after induction of remission and termination of therapy.^{42,186,187} It is characterized by an increase in the serum aminotransferase level to more than 3-fold the upper limit of normal and/or increase in the serum γ -globulin level to more than 2 g/dL.^{15,42,183,184,186} Laboratory changes of this degree are invariably associated with the reappearance of interface hepatitis in the liver tissue, and they preclude the need for a liver biopsy examination to document relapse.⁴² Patients who relapse have a greater frequency of progression to cirrhosis (40% vs. 18%), development of esophageal varices (25% vs. 15%), and death from hepatic failure (15% vs. 4%) than patients who sustain remission after drug withdrawal.^{150,183,184} Only the higher occurrence of drug-related side effects in those who relapse and

require re-treatment, however, distinguishes the groups (54% vs. 26%, $P = .05$).^{150,183,184}

Relapse occurs in from 20% to 100% of patients who enter remission, depending in part on the histologic findings prior to drug withdrawal.^{150,183,186-188} The ideal histologic end point is reversion to normal liver tissue. Adults achieving this result have a 20% frequency of subsequent relapse.¹⁵⁰ In contrast, patients with portal hepatitis at termination of therapy have a 50% frequency of relapse within 6 months,^{150,187} and those who progress to cirrhosis during treatment or who have interface hepatitis at drug withdrawal commonly relapse.¹⁵⁰ Not all patients are able to achieve histologic resolution, and pursuit of this ideal end point must be balanced against the risks associated with the continued administration of medication.¹⁵⁰

Corticosteroids are withdrawn in a gradual fashion over a 6-week period after induction of remission.^{15,183,186} The activity of the disease during and after drug withdrawal is assessed by the appearance of symptoms (fatigue, arthralgias, and anorexia), the nature of the physical findings (jaundice, ascites, and/or peripheral edema), and the behavior of the laboratory indices of liver inflammation (serum aminotransferase and γ -globulin concentrations) and function (serum bilirubin and albumin levels, prothrombin time).⁴² Laboratory tests are performed frequently during drug withdrawal and for 3 months after termination of therapy.¹⁸³⁻¹⁸⁷ They are then repeated at 3 months and then every 6 months for at least 1 year.

Treatment failure connotes clinical, laboratory, and histologic worsening despite compliance with conventional treatment schedules, and it occurs in at least 9% of patients (Table 6).^{15,189} The serum aminotransferase level should increase by at least 67% of the pretreatment value to qualify for this designation.^{15,189} The inability to enter

remission with protracted therapy and the development of drug-induced complications do not represent treatment failure.

Treatment failure justifies the discontinuation of conventional treatments, and institution of high-dose therapy with prednisone alone (60 mg daily) or prednisone (30 mg daily) in conjunction with azathioprine (150 mg daily) (Table 6).^{15,189} Seventy percent of patients improve their clinical and laboratory findings within 2 years, and survival is preserved.¹⁸⁹ Histologic remission is achieved in only 20%, and most patients remain on therapy and at risk for drug-related side effects and/or disease progression. The development of hepatic encephalopathy, ascites, and/or variceal hemorrhage during therapy for treatment failure is an indication for liver transplantation.²⁶

Protracted therapy that has improved the clinical, laboratory, and histologic indices but not induced remission constitutes an incomplete response (Table 6).¹⁹⁰ Thirteen percent of patients experience this outcome. Eighty-seven percent of individuals who enter remission during treatment do so within 3 years. Thereafter, the probability of remission during conventional therapy decreases as the risk of drug-related complications increases.¹⁹⁰ In these instances, alternative strategies must be considered.

Drug toxicity justifies premature discontinuation or alteration of conventional therapy in 13% of patients (Table 6).^{15,150} In these instances, therapy with the tolerated agent (prednisone or azathioprine) can frequently be maintained in adjusted dose to control disease activity.

The treatment end points for children are similar to those of adults. Almost all children demonstrate improvement in liver tests within the first 2 to 4 weeks of treatment with either prednisone or prednisone and azathioprine.^{62,63,156-158} Eighty to 90% achieve laboratory remission in 6 to 12 months. In most treatment protocols, high-dose prednisone (2 mg/kg daily) is administered for up to 2 weeks, at which time a gradual decrease in dose is undertaken to reach a maintenance level (usually 0.1-0.2 mg/kg daily or 5 mg daily) in 6 to 8 weeks (Table 5). Clinical and laboratory parameters rather than histologic findings determine the adequacy of response on therapy. Flares in disease activity, as assessed by an increase in serum aminotransferase level, are treated with a temporary increase in corticosteroid dose.

The goal of treatment in children is to have minimal or no serum aminotransferase abnormality on the lowest dose of medication possible. Long-term, low-dose therapy is anticipated and emotional, cosmetic, and growth-related side effects temper treatment in an individualized fashion. Routine monitoring of conventional liver tests, blood counts, and amylase is performed at 4- to 6-week

intervals. The decision to terminate therapy in children is based on laboratory evidence of prolonged inactivity, and it is a consideration in only 20% to 30% of patients. Drug withdrawal is considered in children who have had normal liver tests and no need for increased corticosteroid dose after 1 to 2 years of treatment. At that time, a liver biopsy examination should be performed and therapy withdrawn only if there is no histologic evidence of inflammation. Relapse after drug withdrawal occurs in 60% to 80% of children, and parents and patients must be informed that the probability of re-treatment is high.^{62,63,156-158}

Recommendations

1. Conventional treatment regimens should be continued in adults and children until remission, treatment failure, incomplete response, or drug toxicity. Once disease remission has been achieved, drug withdrawal should be attempted (Rating, II).

2. Treatment in children should be adjusted to clinical and laboratory findings in an individualized fashion, recognizing that therapy is frequently long term (Rating, III).

Management of Relapse After Drug Withdrawal

Two strategies have been used in adult patients who have relapsed at least twice. The indefinite low-dose prednisone strategy employs the lowest dose of medication possible to prevent symptoms and maintain serum aminotransferase levels below 5-fold normal.¹⁹¹ The prednisone dose is reduced by 2.5 mg each month until the lowest dose is reached below which there is clinical and/or biochemical instability. Serum aminotransferase levels must be checked each month as small decrements in prednisone dose can be associated with marked increases in the serum aminotransferase level.^{191,192} This strategy is most appropriate in patients who are taking prednisone as their sole drug. It can also be applied to individuals taking prednisone and azathioprine. In these latter instances, the dose of prednisone is first reduced to the lowest dose to prevent biochemical instability. Azathioprine is then discontinued as the dose of prednisone is readjusted to compensate for the withdrawal.^{184,191}

Eighty-seven percent of patients can be managed in this fashion on 10 mg of prednisone daily or less (median dose, 7.5 mg daily). Observation intervals for up to 149 months have indicated satisfactory outcomes that have justified continued application of the strategy. Side effects associated with the earlier conventional treatments improve or disappear in 85% of patients; new side effects do not develop; and survival is unaffected.¹⁹¹ The major ad-

vantages of the low-dose prednisone schedule are avoidance of long-term azathioprine therapy in fertile young adults and elimination of the theoretical risks of oncogenicity and teratogenicity.

The indefinite azathioprine strategy substitutes azathioprine for prednisone after induction of remission.^{193,194} The substitution is intended to maintain quiescence of the liver disease indefinitely and avoid corticosteroid-related complications. Application of this strategy is easiest in patients taking prednisone and azathioprine. The dose of azathioprine is increased to 2 mg/kg daily, and then the dose of prednisone is decreased by 2.5 mg each month until complete withdrawal. Patients taking prednisone only can be switched to the azathioprine schedule by adding azathioprine (2 mg/kg daily) and then reducing the prednisone dose by 2.5 mg each month.

Eighty-seven percent of adult patients managed by the indefinite azathioprine strategy remain in remission during a median observation interval of 67 months.¹⁹⁴ Follow-up liver biopsy assessments show inactive or minimal histologic disease in 94% of instances; corticosteroid-related side effects improve or disappear in most patients; and the drug is generally well tolerated.¹⁹⁴ The most common side effect is withdrawal arthralgia, which is encountered in 63% of patients. Myelosuppression occurs in 7%, lymphopenia in 57%; and diverse malignancies in 8%.¹⁹⁴ The major advantage of the azathioprine regimen is the avoidance of corticosteroids and its possible side effects, especially in the postmenopausal patient.

The long-term prednisone and azathioprine strategies for relapse have not been compared head to head in adults, and there are no objective bases for preference. Recent retrospective analyses have indicated that the long-term maintenance therapies need not be life long.¹⁸⁴ Twelve percent of patients treated with these schedules were able to be permanently withdrawn from medication after 69 ± 8 months of follow-up, and the probability of a sustained remission after total drug withdrawal was 13% after 5 years.¹⁸⁴ These observations justify periodic efforts at drug withdrawal in all patients. Bolus regimens of high-dose prednisone¹⁹⁵ and adjunctive treatments with ursodeoxycholic acid¹⁹⁶ and budesonide¹⁹⁷ have not been useful in adults.

Relapse in children is characterized by any manifestation of recrudescence hepatic inflammation after drug withdrawal. Its frequency in children is the same or higher than that observed in adults.^{62,63,156-158,179} The occurrence of relapse in children justifies reinstatement of the original treatment regimen. Indefinite low-dose therapy can then be instituted after suppression of disease activity using prednisone in combination with azathioprine or

6-mercaptopurine.^{62,63,156-158,179} The experience with azathioprine alone as maintenance therapy is limited in children, and the drug is not widely used as the sole medication.

Recommendations

1. Relapse is common in adults and children after drug withdrawal, and patients should be monitored for this occurrence by regular determinations of serum aminotransferase, bilirubin, and γ -globulin levels (Rating, II).

2. Adults who have relapsed more than once should be treated with combination prednisone and azathioprine therapy, low dose prednisone, or azathioprine only (Rating, II).

Management of Suboptimal Responses to Initial Therapy

Treatment failure is managed with high doses of prednisone alone (60 mg daily) or prednisone (30 mg daily) in conjunction with azathioprine (150 mg daily) (Table 6).^{15,189} The regimen is continued for at least 1 month, and then the dose of prednisone is reduced by 10 mg and the dose of azathioprine is reduced by 50 mg after each month of clinical and laboratory improvement. Dose reduction is continued until conventional maintenance levels of medication are again achieved.^{15,189}

Alternative management strategies for treatment failure in adults have included the administration of cyclosporine,¹⁹⁸⁻²⁰³ ursodeoxycholic acid,¹⁹⁶ budesonide,¹⁹⁷ 6-mercaptopurine,²⁰⁴ methotrexate,²⁰⁵ cyclophosphamide,²⁰⁶ and mycophenolate mofetil.²⁰⁷ In each instance, experiences have been small and anecdotal, and in most reports, the preliminary results have been encouraging. Only ursodeoxycholic acid has been evaluated by randomized controlled clinical trial, and it is the one negative experience.¹⁹⁶

Liver transplantation is effective in patients who deteriorate during or after corticosteroid treatment.²⁶⁻²⁹ The 5-year patient and graft survival after liver transplantation in adults ranges from 83% to 92%²⁶⁻²⁹; the actuarial 10-year survival after transplantation is 75%^{29,208}; autoantibodies and hypergammaglobulinemia disappear within 1 year in most patients^{26,27}; and disease recurrence is typically mild and easily managed.²⁷⁻³⁵ Rarely, recurrent AIH may progress to cirrhosis, cause graft failure, and/or be recalcitrant to conventional immunosuppressive regimens.^{28,35,209} In such instances, other agents may be successful in controlling the recurrence as exemplified by a single patient whose recurrent disease progressed during therapy with cyclosporine and corticosteroids but responded after treatment with tacrolimus.²⁰⁹

There are no findings prior to therapy that predict immediate and long-term outcome, and all decompensated patients with severe inflammation should be given a treatment trial of corticosteroids before proceeding with transplantation.¹⁸⁵ Some individuals with advanced liver disease, ascites, and/or endogenous encephalopathy at presentation will improve with treatment and immediate liver transplantation can be avoided.

The likelihood of a significant response to corticosteroid treatment can be determined within 2 weeks.¹⁸⁵ Resolution of at least one laboratory abnormality, improvement in the pretreatment hyperbilirubinemia, and/or failure of any test to worsen during the treatment period indicates that therapy will be effective short term.¹⁸⁵ Conversely, the presence of multiacinar necrosis and a hyperbilirubinemia that does not improve after 2 weeks identifies individuals who will not survive without urgent transplantation.¹⁸⁵ Long-term survival and the ultimate need for liver transplantation also depend on the response to corticosteroid therapy. Inability to induce remission after 4 years of continuous treatment identifies a subgroup of adults at risk for liver failure.²⁶ Liver transplantation should be considered in these individuals at the first sign of decompensation. The development of ascites is the most common indication.²⁶

Treatment failure is noted in 5% to 15% of children with AIH.^{62,63,156-158,179} Children who deteriorate despite compliance with corticosteroid therapy are managed in the same fashion as adults,^{62,63,156-158,179} and liver transplantation is an important treatment option. The frequency of recurrent AIH in the allograft is greater in children than in adults after liver transplantation.³⁵ Recurrent AIH has not been uniformly responsive to treatment, and it has resulted in graft loss in several patients.³⁵

Another confounding factor after transplantation in adults^{210,211} and children²¹²⁻²¹⁴ is the development of AIH *de novo* in the graft. This may occur after transplantation for autoimmune^{210,211} and nonautoimmune diseases.²¹²⁻²¹⁵ *De novo* AIH occurs in 2.5% to 3.4% of allografts, and children seem to have a predilection for the syndrome.²¹²⁻²¹⁴ Immunosuppression with cyclosporine is commonly associated with its occurrence, and the drug may impair thymic negative selection of autoreactive immunocytes.^{212,216} In adults, thymic dysfunction is less likely, but there may be promiscuous lymphocytes that have been primed by repeated exposures to diverse but homologous antigens. These "primed" immunocytes may then target the liver because of molecular mimicry within the liver cells.²¹⁶ Most patients with *de novo* disease respond to prednisone alone or in combination with azathioprine, but fibrosis and graft loss can occur, especially if corticosteroid therapy is not instituted.^{214,215}

An incomplete response is managed empirically by reducing the dose of prednisone to as low as possible to maintain the serum aminotransferase level below 5-fold normal.¹⁹¹ Azathioprine can be used as a corticosteroid-sparing agent, and it can be added to the regimen or increased in dose to 2 mg/kg daily as the dose of prednisone is reduced.^{193,194} Efforts to decrease the dose of medication or eliminate the drugs should be continued throughout follow-up as some patients may achieve remission.¹⁸⁴

Drug toxicity compels immediate adjustments in therapy.^{15,143} Cytopenia, nausea, emotional lability, hypertension, cosmetic changes, and diabetes are typically dose related. These consequences can improve with dose reduction. Severe reactions, including psychosis, extreme cytopenia, and symptomatic osteopenia with or without vertebral compression, justify immediate discontinuation of the offending agent. In these patients, treatment can usually be continued with the single tolerated drug (prednisone or azathioprine) in adjusted dose (Table 6).

Cyclosporine,^{202,203} 6-mercaptopurine,²⁰⁴ cyclophosphamide,²⁰⁶ and mycophenolate mofetil²⁰⁷ have also been used successfully after drug toxicity in isolated cases. In children, concerns about the immediate and long-term consequences of prednisone and azathioprine therapy have generated an enlarging clinical experience with cyclosporine, either as primary or salvage therapy.¹⁸⁰⁻¹⁸² All experiences have been preliminary or anecdotal in nature, and the incorporation of cyclosporine into a standard management algorithm has not been justified.

Recommendations

1. High doses of prednisone alone or prednisone in combination with azathioprine should be used in treatment failure (Rating, III).
2. Corticosteroid therapy should be considered in the decompensated patient (Rating III).
3. Liver transplantation should be considered in the decompensated patient who is unable to undergo or be salvaged by drug therapy (Rating, III).
4. Children who have treatment failure should be treated with high-dose corticosteroid regimens and considered for liver transplantation (Rating, III).

Appendix

The AASLD Practice Guidelines Committee Members are as follows:

Henry C. Bodenheimer, Jr., M.D. (Chair); David Eric Bernstein, M.D.; Gary L. Davis, M.D.; James Everhart, M.D.; Thomas W. Faust, M.D.; Stuart C. Gordon, M.D.; Donald M. Jensen, M.D.; Maureen Jonas, M.D.; Jacob Korula, M.D.; Michael R. Lucey, M.D.; Timothy

M. McCashland, M.D.; Jan M. Novak, M.D.; Melissa Palmer, M.D.; Rajender Reddy, M.D.; Margaret C. Shuhart, M.D.; Thomas Shaw-Stiffel, M.D.; Brent A. Tetri, M.D.

References

- Czaja AJ. Autoimmune hepatitis: evolving concepts and treatment strategies. *Dig Dis Sci* 1995;40:435-456.
- Czaja AJ, Carpenter HA. Sensitivity, specificity and predictability of biopsy interpretations in chronic hepatitis. *Gastroenterology* 1993;105:1824-1832.
- Czaja AJ, Donaldson PT. Genetic susceptibilities for immune expression and liver cell injury in autoimmune hepatitis. *Immunol Rev* 2000;174:250-259.
- Czaja AJ. Understanding the pathogenesis of autoimmune hepatitis. *Am J Gastroenterol* 2001;96:1224-1231.
- Boberg KM, Aadland E, Jahnsen J, Raknerud N, Stiris M, Bell H. Incidence and prevalence of primary biliary cirrhosis, primary sclerosing cholangitis, and autoimmune hepatitis in a Norwegian population. *Scand J Gastroenterol* 1998;33:99-103.
- Milkiewicz P, Hubscher SG, Skiba G, Hathaway M, Elias E. Recurrence of autoimmune hepatitis after liver transplantation. *Transplantation* 1999;68:253-256.
- Wiesner RH, Demetris AJ, Belle SH, Seaberg EC, Lake JR, Zetterman RK, Everhart J, et al. Acute allograft rejection: incidence, risk factors, and impact on outcome. *HEPATOLOGY* 1998;28:638-645.
- Czaja AJ, Dos Santos RM, Porto A, Santrach PJ, Moore SB. Immune phenotype of chronic liver disease. *Dig Dis Sci* 1998;43:2149-2155.
- Gregorio GV, Portmann B, Reid F, Donaldson PT, Doherty DG, McCarty M, Mowat AP, et al. Autoimmune hepatitis in childhood. A 20 year survey. *HEPATOLOGY* 1997;25:541-547.
- Fainboim L, Marcos Y, Pando M, Capucchio M, Reyes GB, Galoppo C, Badia I, et al. Chronic active autoimmune hepatitis in children. Strong association with a particular HLA DR6 (DRB1*1301) haplotype. *Hum Immunol* 1994;41:146-150.
- Seki T, Ota M, Furuta S, Fukushima H, Kondo T, Hino K, Mizuki N, et al. HLA class II molecules and autoimmune hepatitis susceptibility in Japanese patients. *Gastroenterology* 1992;103:1041-1047.
- Bittencourt PL, Goldberg AC, Cancado ELR, Porta G, Laudanna AA, Kalil J. Different HLA profiles confer susceptibility to autoimmune hepatitis type 1 and 2. *Am J Gastroenterol* 1998;93:1394-1395.
- Gupta R, Agarwal SR, Jain M, Malhotra V, Sarin SK. Autoimmune hepatitis in the Indian subcontinent: 7 years experience. *J Gastroenterol Hepatol* 2001;16:1144-1148.
- Lim KN, Casanova RL, Boyer TD, Bruno CJ. Autoimmune hepatitis in African Americans: presenting features and response to therapy. *Am J Gastroenterol* 2001;96:3390-3394.
- Soloway RD, Summerskill WHJ, Baggenstoss AH, Geall MG, Gitnick GL, Elveback LR, Schoenfield LJ. Clinical, biochemical, and histological remission of severe chronic active liver disease: a controlled study of treatments and early prognosis. *Gastroenterology* 1972;63:820-833.
- Mistilis SP, Skyring AP, Blackburn CRB. Natural history of active chronic hepatitis. I. Clinical features, course, diagnostic criteria, morbidity, mortality, and survival. *Australas Ann Med* 1968;17:214-223.
- Murray-Lyon IM, Stern RB, Williams R. Controlled trial of prednisone and azathioprine in active chronic hepatitis. *Lancet* 1973;1:735-737.
- Schalm SW, Korman MG, Summerskill WHJ, Czaja AJ, Baggenstoss AH. Severe chronic active liver disease. Prognostic significance of initial morphologic patterns. *Am J Dig Dis* 1977;22:973-980.
- DeGroote J, Fevery J, Lepoutre L. Long-term follow-up of chronic active hepatitis of moderate severity. *Gut* 1978;19:510-513.
- Czaja AJ, Davis GL, Ludwig J, Baggenstoss AH, Taswell HF. Autoimmune features as determinants of prognosis in steroid-treated chronic active hepatitis of uncertain etiology. *Gastroenterology* 1983;85:713-717.
- Crapper RM, Bhathal PS, Mackay IR, Frazer IH. "Acute" autoimmune hepatitis. *Digestion* 1986;34:216-225.
- Amontree JS, Stuart TD, Bredfeldt JE. Autoimmune chronic active hepatitis masquerading as acute hepatitis. *J Clin Gastroenterol* 1989;11:303-307.
- Nikias GA, Batts KP, Czaja AJ. The nature and prognostic implications of autoimmune hepatitis with an acute presentation. *J Hepatol* 1994;21:866-871.
- Porta G, Da Costa Gayotto LC, Alvarez F. Anti-liver-kidney microsome antibody-positive autoimmune hepatitis presenting as fulminant liver failure. *J Ped Gastroenterol Nutrition* 1990;11:138-140.
- Cook GC, Mulligan R, Sherlock S. Controlled prospective trial of corticosteroid therapy in active chronic hepatitis. *Q J Med* 1971;40:159-185.
- Sanchez-Urdazpal L, Czaja AJ, van Hoek B, Krom RAF, Wiesner RH. Prognostic features and role of liver transplantation in severe corticosteroid-treated autoimmune chronic active hepatitis. *HEPATOLOGY* 1992;15:215-221.
- González-Koch A, Czaja AJ, Carpenter HA, Roberts SK, Charlton MR, Porayko MK, Rosen CB, et al. Recurrent autoimmune hepatitis after orthotopic liver transplantation. *Liver Transplantation* 2001;4:302-310.
- Ratziu V, Samuel D, Sebah M, Farges O, Saliba F, Ichai P, Farahmand H, et al. Long-term follow-up after liver transplantation for autoimmune hepatitis: evidence of recurrence of primary disease. *J Hepatol* 1999;30:131-141.
- Ahmed M, Mutimer D, Hathaway M, Hubscher S, McMaster P, Elias E. Liver transplantation for autoimmune hepatitis: a 12-year experience. *Transplantation Proceedings* 1997;29:496.
- Neuberger J, Portmann B, Calne R, Williams R. Recurrence of autoimmune chronic active hepatitis following orthotopic liver grafting. *Transplantation* 1984;37:363-365.
- Wright HL, Bou-Abboud CF, Hassanein T, Block GD, Demetris AJ, Starzl TE, Van Thiel DH. Disease recurrence and rejection following liver transplantation for autoimmune chronic active liver disease. *Transplantation* 1992;53:136-139.
- Devlin J, Donaldson P, Portmann B, Heaton N, Tan K-C, Williams R. Recurrence of autoimmune hepatitis following liver transplantation. *Liver Transplantation Surg* 1995;1:162-165.
- Prados E, Cuervas-Mons V, de la Mata M, Fraga E, Rimola A, Prieto M, Clemente G, et al. Outcome of autoimmune hepatitis after liver transplantation. *Transplantation* 1998;66:1645-1650.
- Gotz G, Neuhaus R, Bechstein WO, Lobeck H, Berg T, Hopf U, Neuhaus P. Recurrence of autoimmune hepatitis after liver transplantation. *Transplantation Proceedings* 1999;31:430-431.
- Birnbaum AH, Benkov KJ, Pittman NS, McFarlane-Ferreira Y, Rosh JR, LeLeiko NS. Recurrence of autoimmune hepatitis in children after liver transplantation. *J Pediatr Gastroenterol Nutr* 1997;25:20-25.
- Johnson PJ, McFarlane IG, Alvarez F, Bianchi FB, Bianchi L, Burroughs A, Chapman RW, et al. Meeting Report. International Autoimmune Hepatitis Group. *HEPATOLOGY* 1993;18:998-1005.
- Alvarez F, Berg PA, Bianchi FB, Burroughs AK, Cancado EL, Chapman RW, et al. International Autoimmune Hepatitis Group report: review of criteria for diagnosis of autoimmune hepatitis. *J Hepatol* 1999;31:929-938.
- Frazer IH, Mackay IR, Bell J, Becker G. The cellular infiltrate in the liver in autoimmune chronic active hepatitis: analysis with monoclonal antibodies. *Liver* 1985;5:162-172.
- Bach N, Thung SN, Schaffner F. The histological features of chronic hepatitis C and autoimmune chronic hepatitis: a comparative analysis. *HEPATOLOGY* 1992;15:572-577.
- Scheuer PJ, Ashrafzadeh P, Sherlock S, Brown D, Dusheiko GM. The pathology of hepatitis C. *HEPATOLOGY* 1992;15:567-571.
- Czaja AJ, Carpenter HA. Histological findings in chronic hepatitis C with autoimmune features. *HEPATOLOGY* 1997;26:459-466.
- Czaja AJ, Wolf AM, Baggenstoss AH. Laboratory assessment of severe chronic active liver disease (CALD): correlation of serum transaminase and gamma globulin levels with histologic features. *Gastroenterology* 1981;80:687-692.

43. Czaja AJ. Frequency and nature of the variant syndromes of autoimmune liver disease. *HEPATOLOGY* 1998;28:360-365.
44. Czaja AJ, Carpenter HA, Santrach PJ, Moore SB. Autoimmune cholangitis within the spectrum of autoimmune liver disease. *HEPATOLOGY* 2000;31:1231-1238.
45. Czaja AJ, Carpenter HA. Autoimmune hepatitis with incidental histologic features of bile duct injury. *HEPATOLOGY* 2001;34:659-665.
46. Ben-Ari Z, Czaja AJ. Autoimmune hepatitis and its variant syndromes. *Gut* 2001;49:589-594.
47. Czaja AJ, Carpenter HA, Santrach PJ, Moore SB. Host- and disease-specific factors affecting steatosis in chronic hepatitis C. *J Hepatol* 1998;29:198-206.
48. Czaja AJ. Autoantibodies. *Bailliere's Clin Gastroenterol* 1995;9:723-744.
49. Czaja AJ, Homburger HA. Autoantibodies in liver disease. *Gastroenterology* 2001;120:239-249.
50. Czaja AJ, Carpenter HA. Validation of a scoring system for the diagnosis of autoimmune hepatitis. *Dig Dis Sci* 1996;41:305-314.
51. Bianchi FB, Cassani F, Lenzi M, Ballardini G, Muratori L, Giostra F, Zauli D. Impact of International Autoimmune Hepatitis Group scoring system in definition of autoimmune hepatitis. An Italian experience. *Dig Dis Sci* 1996;41:166-171.
52. Toda G, Zeniya M, Watanabe F, Imawari M, Kiyosawa K, Nishioka M, Tsuji T, Omata M. Present status of autoimmune hepatitis in Japan—correlating the characteristics with international criteria in an area with a high rate of HCV infection. *J Hepatol* 1997;26:1207-1212.
53. Miyakawa H, Kitazawa E, Abe K, Kawaguchi N, Fuzikawa H, Kikuchi K, Kato M, et al. Chronic hepatitis C associated with anti-liver/kidney microsome-1 antibody is not a subgroup of autoimmune hepatitis. *J Gastroenterol* 1997;32:769-776.
54. Dickson RC, Gaffey MJ, Ishitani MB, Roarty TP, Driscoll CJ, Caldwell SH. The international autoimmune hepatitis score in chronic hepatitis C. *J Viral Hep* 1997;4:121-128.
55. Boberg KM, Fausa O, Haaland T, Holter E, Mellbye OJ, Spurkland A, Schrupf E. Features of autoimmune hepatitis in primary sclerosing cholangitis: an evaluation of 114 primary sclerosing cholangitis patients according to a scoring system for the diagnosis of autoimmune hepatitis. *HEPATOLOGY* 1996;23:1369-1376.
56. Omagari K, Masuda J, Kato Y, Nakata K, Kanematsu T, Kusumoto Y, Mori I, et al. Re-analysis of clinical features of 89 patients with autoimmune hepatitis using the revised scoring system proposed by the International Autoimmune Hepatitis Group. *Intern Med* 2000;39:1008-1012.
57. Czaja AJ. Behavior and significance of autoantibodies in type 1 autoimmune hepatitis. *J Hepatol* 1999;30:394-401.
58. Czaja AJ, Carpenter HA, Santrach PJ, Moore SB, Homburger HA. The nature and prognosis of severe cryptogenic chronic active hepatitis. *Gastroenterology* 1993;104:1755-1761.
59. Czaja AJ. Chronic active hepatitis: the challenge for a new nomenclature. *Ann Intern Med* 1993;119:510-517.
60. Czaja AJ, Carpenter HA, Manns MP. Antibodies to soluble liver antigen, P450IID6, and mitochondrial complexes in chronic hepatitis. *Gastroenterology* 1993;105:1522-1528.
61. Czaja AJ, Pfeifer KD, Decker RH, Vallari AS. Frequency and significance of antibodies to asialoglycoprotein receptor in type 1 autoimmune hepatitis. *Dig Dis Sci* 1996;41:1733-1740.
62. Gregorio GV, Portmann B, Reid F, Donaldson PT, Doherty DG, McCartney M, Mowat AP, et al. Autoimmune hepatitis in childhood. A 20 year survey. *HEPATOLOGY* 1997;25:541-547.
63. Gregorio GV, Portmann B, Karani J, Harrison P, Donaldson PT, Vergani D, Mieli-Vergani G. Autoimmune hepatitis/sclerosing cholangitis overlap syndrome in childhood: a 16-year prospective study. *HEPATOLOGY* 2001;33:544-553.
64. Czaja AJ, Nishioka M, Morshed SA, Hachiya T. Patterns of nuclear immunofluorescence and reactivities to recombinant nuclear antigens in autoimmune hepatitis. *Gastroenterology* 1994;107:200-207.
65. Homburger HA, Cahen YD, Griffiths J, Jacob GL. Detection of antinuclear antibodies. Comparative evaluation of enzyme immunoassay and indirect immunofluorescence methods. *Arch Pathol Lab Med* 1998;122:993-999.
66. Czaja AJ, Cassani F, Cataleta M, Valentini P, Bianchi FB. Antinuclear antibodies and patterns of nuclear immunofluorescence in type 1 autoimmune hepatitis. *Dig Dis Sci* 1997;42:1688-1696.
67. Bernstein RM, Neuberger JM, Bunn CC, Callender ME, Hughes GRV, Williams R. Diversity of autoantibodies in primary biliary cirrhosis and chronic active hepatitis. *Clin Exp Immunol* 1984;55:553-560.
68. Chou M-J, Lee S-L, Chen T-Y, Tsay GJ. Specificity of antinuclear antibodies in primary biliary cirrhosis. *Ann Rheum Dis* 1995;54:148-151.
69. Czaja AJ, Carpenter HA, Santrach PJ, Moore SB. Genetic predispositions for immunological features in chronic liver diseases other than autoimmune hepatitis. *J Hepatol* 1996;24:52-59.
70. Czaja AJ, Santrach PJ, Moore SB. Shared genetic risk factors in autoimmune liver disease. *Dig Dis Sci* 2001;46:140-147.
71. Czaja AJ, Carpenter HA, Santrach PJ, Moore SB. Genetic predispositions for the immunological features of chronic active hepatitis. *HEPATOLOGY* 1993;18:816-822.
72. Czaja AJ, Carpenter HA, Santrach PJ, Moore SB. Immunologic features and HLA associations in chronic viral hepatitis. *Gastroenterology* 1995;108:157-164.
73. Maddrey WC, Boitnott JK. Drug-induced chronic liver disease. *Gastroenterology* 1977;72:1348-1353.
74. Seeff LB. Drug-induced chronic liver disease, with emphasis on chronic active hepatitis. *Semin Liver Dis* 1981;1:104-115.
75. Hay JE, Czaja AJ, Rakela J, Ludwig J. The nature of unexplained chronic aminotransferase elevations of a mild to moderate degree in asymptomatic patients. *HEPATOLOGY* 1989;9:193-197.
76. Kurki P, Gripenberg M, Teppo A-M, Salaspuro M. Profiles of antinuclear antibodies in chronic active hepatitis, primary biliary cirrhosis and alcoholic liver disease. *Liver* 1984;4:134-138.
77. Konikoff F, Isenberg DA, Barrison I, Theodor E, Shoenfeld Y. Antinuclear autoantibodies in chronic liver diseases. *Hepato-gastroenterol* 1989;36:341-345.
78. Whittingham S, Irwin J, Mackay IR, Smalley M. Smooth muscle autoantibody in "autoimmune" hepatitis. *Gastroenterology* 1966;51:499-505.
79. Bottazzo GF, Florin-Christensen A, Fairfax A, Swana G, Doniach D, Groeschel-Stewart U. Classification of smooth muscle autoantibodies (SMA) detected by immunofluorescence. *J Clin Path* 1976;29:403-410.
80. Toh B-H. Smooth muscle autoantibody and autoantigens. *Clin Exp Immunol* 1979;38:621-628.
81. Czaja AJ, Cassani F, Cataleta M, Valentini P, Bianchi FB. Frequency and significance of antibodies to actin in type 1 autoimmune hepatitis. *HEPATOLOGY* 1996;24:1068-1073.
82. Homburger J-C, Abuaf N, Bernard O, Islam S, Alvarez F, Khalil SH, Poupon R, et al. Chronic active hepatitis associated with antiliver/kidney microsome antibody type 1: a second type of "autoimmune" hepatitis. *HEPATOLOGY* 1987;7:1333-1339.
83. Czaja AJ, Manns MP, Homburger HA. Frequency and significance of antibodies to liver/kidney microsome type 1 in adults with chronic active hepatitis. *Gastroenterology* 1992;103:1290-1295.
84. Manns MP, Griffin KJ, Sullivan KF, Johnson EF. LKM-1 autoantibodies recognize a short linear sequence in P450IID6, a cytochrome P-450 monooxygenase. *J Clin Invest* 1991;88:1370-1378.
85. Manns M, Zanger U, Gerken G, Sullivan KF, Meyer zum Buschenfelde K-H, Meyer UA, Eichelbaum M. Patients with type II autoimmune hepatitis express functionally intact cytochrome P-450 db1 that is inhibited by LKM-1 autoantibodies in vitro but not in vivo. *HEPATOLOGY* 1990;12:127-132.
86. Lohr H, Manns M, Kyriatsoulis A, Lohse AW, Trautwein C, Meyer zum Buschenfelde K-H, Fleischer B. Clonal analysis of liver-infiltrating T cells in patients with LKM-1 antibody-positive autoimmune chronic active hepatitis. *Clin Exp Immunol* 1991;84:297-302.
87. Todros L, Touscoz G, D'Urso N, Durazzo M, Albano E, Poli G, Baldi M, et al. Hepatitis C virus-related chronic liver disease with autoantibodies to

- liver-kidney microsomes (LKM). Clinical characterization from idiopathic LKM-positive disorders. *J Hepatol* 1991;13:128-131.
88. Lunel F, Abuaf N, Frangeul L, Gripon P, Perrin M, Le Coz Y, Valla D, et al. Liver/kidney microsome antibody type 1 and hepatitis C virus infection. *HEPATOLOGY* 1992;16:630-636.
 89. Giostra F, Manzin A, Lenzi M, Francesconi R, Solforosi L, Manotti P, Muratori L, et al. Low hepatitis C viremia in patients with anti-liver/kidney microsomal antibody type 1 positive chronic hepatitis. *J Hepatol* 1996;25:433-438.
 90. Mackie FD, Peakman M, Yun M, Sallies R, Smoth H, Davies ET, Mieli-Vergani G, et al. Primary and secondary liver/kidney microsomal autoantibody response following infection with hepatitis C virus. *Gastroenterology* 1994;106:1672-1675.
 91. Reddy RK, Krawitt EL, Homberg JC, Jeffers LJ, deMedina M, Chastenay B, Poupon R, et al. Absence of anti-LKM1 in hepatitis C viral infection in the United States. *J Viral Hepat* 1995;2:175-179.
 92. Michitaka K, Durazzo M, Tillmann HL, Walker D, Philipp T, Manns MP. Analysis of hepatitis C virus genome in patients with autoimmune hepatitis type 2. *Gastroenterology* 1994;106:1603-1610.
 93. Gerotto M, Pontisso P, Giostra F, Francesconi R, Muratori L, Ballardini G, Lenzi M, et al. Analysis of the hepatitis C virus genome in patients with anti-LKM-1 autoantibodies. *J Hepatol* 1994;21:273-276.
 94. Yamamoto AM, Cresteil D, Homberg JC, Alvarez F. Characterization of the anti-liver-kidney microsome antibody (anti-LKM1) from hepatitis C virus-positive and -negative sera. *Gastroenterology* 1993;104:1762-1767.
 95. Czaja AJ, Kruger M, Santrach PJ, Moore SB, Manns MP. Genetic distinctions between types 1 and 2 autoimmune hepatitis. *Am J Gastroenterol* 1997;92:2197-2200.
 96. Bittencourt PL, Goldberg AC, Cancado ELR, Porta G, Carrilho FJ, Farias AQ, Palacios SA, et al. Genetic heterogeneity in susceptibility to autoimmune hepatitis types 1 and 2. *Am J Gastroenterol* 1999;94:1906-1913.
 97. Czaja AJ, Manns MP. The validity and importance of subtypes of autoimmune hepatitis: a point of view. *Am J Gastroenterol* 1995;90:1206-1211.
 98. Targan SR, Landers C, Vidrich A, Czaja AJ. High-titer antineutrophil cytoplasmic antibodies in type 1 autoimmune hepatitis. *Gastroenterology* 1995;108:1159-1166.
 99. Mulder AHL, Horst G, Haagsma EB, Limburg PC, Kleibeuker JH, Kallenberg CGM. Prevalence and characterization of neutrophil cytoplasmic antibodies in autoimmune liver diseases. *HEPATOLOGY* 1993;17:411-417.
 100. Zauli D, Ghetti S, Grassi A, Descovich C, Cassani F, Ballardini G, Muratori L, Bianchi FB. Anti-neutrophil cytoplasmic antibodies in type 1 and type 2 autoimmune hepatitis. *HEPATOLOGY* 1997;25:1105-1107.
 101. LaBrecque DR, Phillips MJP, Ippolito LA, Mitros FA, Goeken JA. Antineutrophil cytoplasmic antibody and chronic liver disease [abstract]. *HEPATOLOGY* 1999;30(Part 2):428A.
 102. Duerr RH, Targan SR, Landers CJ, LaRusso NF, Lindsay KL, Wiesner RH, Shanahan F. Neutrophil cytoplasmic antibodies: a link between primary sclerosing cholangitis and ulcerative colitis. *Gastroenterology* 1991;100:1385-1391.
 103. Bansi D, Chapman R, Fleming K. Antineutrophil cytoplasmic antibodies in chronic liver diseases: prevalence, titre, specificity and IgG subclass. *J Hepatol* 1996;24:581-586.
 104. Lidman K, Biberfeld G, Fagraeus A, Norberg R, Tortensson R, Utter G, Carlsson L, et al. Anti-actin specificity of human smooth muscle antibodies in chronic active hepatitis. *Clin Exp Immunol* 1976;24:266-272.
 105. Cancado ELR, Vilas-Boas LS, Abrantes-Lemos CP, Novo NF, Porta G, Da Silva LC, Laudanna AA. Heat serum inactivation as a mandatory procedure for antiactin antibody detection in cell culture. *HEPATOLOGY* 1996;23:1098-1104.
 106. McFarlane IG, McFarlane BM, Major GN, Tolley P, Williams R. Identification of the hepatic asialo-glycoprotein receptor (hepatic lectin) as a component of liver specific membrane lipoprotein (LSP). *Clin Exp Immunol* 1984;55:347-354.
 107. Treichel U, Poralla T, Hess G, Manns M, Meyer zum Buschfelde K-H. Autoantibodies to human asialoglycoprotein receptor in autoimmune-type chronic hepatitis. *HEPATOLOGY* 1990;11:606-612.
 108. Poralla T, Treichel U, Lohr H, Fleischer B. The asialoglycoprotein receptor as target structure in autoimmune liver diseases. *Semin Liver Dis* 1991;11:215-222.
 109. McFarlane IG, Hegarty JE, McSorley CG, McFarlane BM, Williams R. Antibodies to liver-specific protein predict outcome of treatment withdrawal in autoimmune chronic active hepatitis. *Lancet* 1984;2:954-956.
 110. Treichel U, Gerken G, Rossol S, Rothauwe HW, Meyer zum Buschenfelde K-H, Poralla T. Autoantibodies against the human asialoglycoprotein receptor: effects of therapy in autoimmune and virus-induced chronic active hepatitis. *J Hepatol* 1993;19:55-63.
 111. Czaja AJ, Pfeifer KD, Decker RH, Vallari AS. Frequency and significance of antibodies to asialoglycoprotein receptor in type 1 autoimmune hepatitis. *Dig Dis Sci* 1996;41:1733-1740.
 112. Baeres M, Herkel J, Czaja AJ, Wies I, Kanzler S, Cancado EL, Porta G, et al. Establishment of a standardized SLA/LP immunoassay: specificity for autoimmune hepatitis, worldwide occurrence and clinical characteristics. *Gut* (in press).
 113. Wies I, Brunner S, Henninger J, Herkel J, Meyer zum Buschenfelde KH, Lohse AW. Identification of target antigen for SLA/LP autoantibodies in autoimmune hepatitis. *Lancet* 2000;355:1510-1515.
 114. Costa M, Rodrigues-Sanchez JL, Czaja AJ, Gelpi C. Isolation and characterization of cDNA encoding the antigenic protein of the human tRNA^(Ser)Sec complex recognized by autoantibodies from patients with type 1 autoimmune hepatitis. *Clin Exp Immunol* 2000;121:364-374.
 115. Kernebeck T, Lohse AW, Grotzinger J. A bioinformatical approach suggests the function of the autoimmune hepatitis target soluble liver antigen/liver pancreas. *HEPATOLOGY* 2001;34:230-233.
 116. Kanzler S, Weidemann C, Gerken G, Lohr HF, Galle PR, Meyer zum Buschenfelde KH, Lohse AW. Clinical significance of autoantibodies to soluble liver antigen in autoimmune hepatitis. *J Hepatol* 1999;31:635-640.
 117. Czaja AJ, Donaldson PT, Lohse AW. Antibodies to soluble liver antigen/liver pancreas and HLA risk factors in type 1 autoimmune hepatitis. *Am J Gastroenterol* 2002;97:413-419.
 118. Volkmann M, Martin L, Baurle A, Heid H, Strassburg CP, Trautwein C, Fiehn W, et al. Soluble liver antigen: isolation of a 35-kd recombinant protein (SLA-p35) specifically reacts with sera from patients with autoimmune hepatitis. *HEPATOLOGY* 2001;33:591-596.
 119. Lapierre P, Hajoui O, Homberg J-C, Alvarez F. Formiminotransferase cyclodeaminase is an organ-specific autoantigen recognized by sera of patients with autoimmune hepatitis. *Gastroenterology* 1999;116:643-649.
 120. Muratori L, Sztul E, Muratori P, Gao YS, Ripalti A, Ponti C, Lenzi M, et al. Distinct epitopes on formiminotransferase cyclodeaminase induce autoimmune liver cytosol antibody type 1. *HEPATOLOGY* 2001;34:494-501.
 121. Pelli N, Fensom AH, Slade C, Boa F, Mieli-Vergani G, Vergani D. Argininosuccinate lyase: a new autoantigen in liver disease. *Clin Exp Immunol* 1998;114:455-461.
 122. Abuaf N, Johanet C, Chretien P, Martini E, Soulier E, Laperche S, Homberg JC. Characterization of the liver cytosol antigen type 1 reacting with autoantibodies in chronic active hepatitis. *HEPATOLOGY* 1992;16:892-898.
 123. Martini E, Abuaf N, Cavalli F, Durand V, Johanet C, Homberg J-C. Antibody to liver cytosol (anti-LC1) in patients with autoimmune chronic active hepatitis type 2. *HEPATOLOGY* 1988;8:1662-1666.
 124. Han S, Tredger M, Gregorio GV, Mieli-Vergani G, Vergani D. Anti-liver cytosolic antigen type 1 (LC1) antibodies in childhood autoimmune liver disease. *HEPATOLOGY* 1995;21:58-62.
 125. Muratori L, Cataleta M, Muratori P, Lenzi M, Bianchi FB. Liver/kidney microsomal antibody type 1 and liver cytosol antibody type 1 concentrations in type 2 autoimmune hepatitis. *Gut* 1998;42:721-726.
 126. Manns M, Gerken G, Kyriatsoulis A, Staritz M, Meyer zum Buschenfelde KH. Characterization of a new subgroup of autoimmune chronic active

- hepatitis by autoantibodies against a soluble liver antigen. *Lancet* 1987; 1:292-294.
127. Stechemesser E, Klein R, Berg PA. Characterization and clinical relevance of liver-pancreas antibodies in autoimmune hepatitis. *HEPATOLOGY* 1993;18:1-9.
 128. Donaldson PT, Doherty DG, Hayllar KM, McFarlane IG, Johnson PJ, Williams R. Susceptibility to autoimmune chronic active hepatitis: human leukocyte antigens DR4 and A1-B8-DR3 are independent risk factors. *HEPATOLOGY* 1991;13:701-706.
 129. Strettell MDJ, Donaldson PT, Thomson LJ, Santrach PJ, Moore SB, Czaja AJ, Williams R. Allelic basis for HLA-encoded susceptibility to type 1 autoimmune hepatitis. *Gastroenterology* 1997;112:2028-2035.
 130. Czaja AJ, Strettell MDJ, Thomson LJ, Santrach PJ, Moore SB, Donaldson PT, Williams R. Associations between alleles of the major histocompatibility complex and type 1 autoimmune hepatitis. *HEPATOLOGY* 1997; 25:317-323.
 131. Czaja AJ, Rakela J, Hay JE, Moore SB. Clinical and prognostic implications of human leukocyte antigen B8 in corticosteroid-treated severe autoimmune chronic active hepatitis. *Gastroenterology* 1990;98:1587-1593.
 132. Czaja AJ, Carpenter HA, Santrach PJ, Moore SB. Significance of HLA DR4 in type 1 autoimmune hepatitis. *Gastroenterology* 1993;105:1502-1507.
 133. Clemente MG, Obermayer-Straub P, Meloni A, Strassburg CP, Arangino V, Tukey RH, De Virgiliis S, et al. Cytochrome P450 1A2 is a hepatic autoantigen in autoimmune polyglandular syndrome type 1. *J Clin Endocrinol Metab* 1997;82:1353-1361.
 134. Clemente MG, Meloni A, Obermayer-Straub P, Frau F, Manns MP, De Virgiliis S. Two cytochromes P450 are major hepatocellular autoantigens in autoimmune polyglandular syndrome type 1. *Gastroenterology* 1998; 114:324-328.
 135. Obermayer-Straub P, Perheentupa J, Braun S, Kayser A, Barut A, Loges S, Harms A, et al. Hepatic autoantigens in patients with autoimmune polyendocrinopathy-candidiasis-ectodermal dystrophy. *Gastroenterology* 2001;121:668-677.
 136. Consortium TF-GA. An autoimmune disease, APECED, caused by mutations in a novel gene featuring two PHD-type zinc finger domains. *Nat Genet* 1997;17:399-403.
 137. Aaltonen J, Borsos P, Sandkuijl L, Perheentupa J, Peltonen L. An autosomal locus causing autoimmune disease: autoimmune polyglandular disease type 1 assigned to chromosome 21. *Nat Genet* 1994;8:83-87.
 138. Nagamine K, Peterson P, Scott HS, Kudoh J, Minooshima S, Heino M, Krohn KJE, et al. Positional cloning of the APECED gene. *Nat Genet* 1997;17:393-398.
 139. Roberts SK, Therneau T, Czaja AJ. Prognosis of histological cirrhosis in type 1 autoimmune hepatitis. *Gastroenterology* 1996;110:848-857.
 140. Koretz RL, Lewin KJ, Higgins J, Fagen ND, Gitnick GL. Chronic active hepatitis. Who meets treatment criteria? *Dig Dis Sci* 1980;25:695-699.
 141. Baggenstoss AH, Soloway RD, Summerskill WHJ, Elveback LR, Schoenfeld LJ. Chronic active liver disease. The range of histologic lesions, their response to treatment, and evolution. *Hum Pathol* 1972;3:183-198.
 142. Czaja AJ, Taswell HF, Rakela J, Schimek C. Frequency of antibody to hepatitis C virus in asymptomatic HBsAg negative chronic active hepatitis. *J Hepatol* 1992;14:88-93.
 143. Summerskill WHJ, Korman MG, Ammon HV, Baggenstoss AH. Prednisone for chronic active liver disease: dose titration, standard dose, and combination with azathioprine compared. *Gut* 1975;16:876-883.
 144. Lewis GP, Jusko WJ, Burke CW, Graves L. Prednisone side-effects and serum protein levels: a collaborative study. *Lancet* 1971;2:778-781.
 145. Uribe M, Go VLW, Kluge D. Prednisone for chronic active hepatitis: pharmacokinetics and serum binding in patients with chronic active hepatitis and steroid major side effects. *J Clin Gastroenterol* 1984;6:331-335.
 146. Stellon AJ, Davies A, Compston J, Williams R. Bone loss in autoimmune chronic active hepatitis on maintenance corticosteroid therapy. *Gastroenterology* 1985;89:1078-1083.
 147. Lebovics E, Schaffner F, Klion EM, Simon C. Autoimmune chronic active hepatitis in postmenopausal women. *Dig Dis Sci* 1985;30:824-828.
 148. Wang KK, Czaja AJ. Prognosis of corticosteroid-treated hepatitis B surface antigen-negative chronic active hepatitis in postmenopausal women: a retrospective analysis. *Gastroenterology* 1989;97:1288-1293.
 149. Davis GL, Czaja AJ, Ludwig J. Development and prognosis of histologic cirrhosis in corticosteroid-treated HBsAg-negative chronic active hepatitis. *Gastroenterology* 1984;87:1222-1227.
 150. Czaja AJ, Davis GL, Ludwig J, Taswell HF. Complete resolution of inflammatory activity following corticosteroid treatment of HBsAg-negative chronic active hepatitis. *HEPATOLOGY* 1984;4:622-627.
 151. Steven MM, Buckley JD, Mackay IR. Pregnancy in chronic active hepatitis. *QJM* 1979;48:519-531.
 152. Lee MG, Hanchard B, Donaldson EK, Charles C, Hall JStE. Pregnancy in chronic active hepatitis with cirrhosis. *J Trop Med Hyg* 1987;90:245-248.
 153. Heneghan MA, Norris SM, O'Grady JG, Harrison PM, McFarlane IG. Management and outcome of pregnancy in autoimmune hepatitis. *Gut* 2001;48:97-102.
 154. Rosenkrantz JG, Githens JH, Cox SM, Kellum DL. Azathioprine (Imuran) and pregnancy. *Am J Obstet Gynecol* 1967 97:387-394.
 155. Varma RR, Michelsohn NH, Borkowf HI, Lewis JD. Pregnancy in cirrhotic and noncirrhotic portal hypertension. *Obstet Gynecol* 1977;50: 217-222.
 156. Maggiore G, Bernard O, Hadchouel M, Hadchouel P, Odievre M, Alagille D. Treatment of autoimmune chronic active hepatitis in childhood. *J Pediatr* 1984;104:839-844.
 157. Maggiore G, Veber F, Bernard O, Hadchouel M, Homberg JC, Alvarez F, Hadchouel P, et al. Autoimmune hepatitis associated with anti-actin antibodies in children and adolescents. *J Pediatr Gastroenterol Nutr* 1993;17:376-381.
 158. Roberts EA. Autoimmune hepatitis. *Indian J Pediatr* 1995;62:525-531.
 159. Schalm SW, Summerskill WHJ, Go VLW. Prednisone for chronic active liver disease: pharmacokinetics, including conversion to prednisolone. *Gastroenterology* 1977;72:910-913.
 160. DePinho RA, Goldberg CS, Lefkowitz JH. Azathioprine and the liver. Evidence favoring idiosyncratic, mixed cholestatic-hepatocellular injury in humans. *Gastroenterology* 1984;86:162-165.
 161. Read AE, Wiesner RH, LaBrecque DR, Tiff JG, Mullen KD, Sheer RL, Petrelli M, et al. Hepatic veno-occlusive disease associated with renal transplantation and azathioprine therapy. *Ann Int Med* 1986;104:651-655.
 162. Katzka DA, Saul SH, Jorkasky D, Sigal H, Reynolds JC, Soloway RD. Azathioprine and hepatic venoocclusive disease in renal transplant patients. *Gastroenterology* 1986;90:446-454.
 163. Eland IA, van Puijenbroek EP, Sturkenboom MJ, Wilson JH, Stricker BH. Drug-associated acute pancreatitis: twenty-one years of spontaneous reporting in The Netherlands. *Am J Gastroenterol* 1999;94:2417-2422.
 164. Tragnone A, Bzzocchi G, Aversa G, Pecorellia MG, Elmi G, Venerato S, Lanfranchi GA. Acute pancreatitis after azathioprine treatment for ulcerative colitis. *Ital J Gastroenterol* 1996;28:102-104.
 165. Lennard L, Van Loon JA, Weinshilboum RM. Pharmacokinetics of acute azathioprine toxicity: relationship to thiopurine methyltransferase genetic polymorphism. *Clin Pharmacol Ther* 1989;46:149-154.
 166. Ben Ari Z, Mehta A, Lennard L, Burroughs AK. Azathioprine-induced myelosuppression due to thiopurine methyltransferase deficiency in a patient with autoimmune hepatitis. *J Hepatol* 1995;23:351-354.
 167. Lennard L. Clinical implications of thiopurine methyltransferase-optimization of drug dosage and potential drug interactions. *Therap Drug Monit* 1998;20:527-531.
 168. Yates CR, Krynetski EY, Loennechen T, Fessing MY, Tai H-L, Pui C-H, Relling MV, et al. Molecular diagnosis of thiopurine S-methyltransferase deficiency: genetic basis for azathioprine and mercaptopurine intolerance. *Ann Int Med* 1997;126:608-614.
 169. Heneghan MA, McFarlane IG. Current and novel immunosuppressive therapy for autoimmune hepatitis. *HEPATOLOGY* 2002;35:7-13.

170. Penn I. Tumor incidence in allograft recipients. *Transplant Proc* 1979; 11:1047-1051.
171. Aguilar HI, Burgart LJ, Geller A, Rakela J. Azathioprine-induced lymphoma manifesting as fulminant hepatic failure. *Mayo Clin Proc* 1997; 72:643-645.
172. Wang KK, Czaja AJ, Beaver SJ, Go VLW. Extrahepatic malignancy following long-term immunosuppressive therapy of severe hepatitis B surface antigen-negative chronic active hepatitis. *HEPATOLOGY* 1989;10:39-43.
173. Wang KK, Czaja AJ. Hepatocellular cancer in corticosteroid-treated severe autoimmune chronic active hepatitis. *HEPATOLOGY* 1988;8:1679-1683.
174. Park SZ, Nagorney DM, Czaja AJ. Hepatocellular carcinoma in autoimmune hepatitis. *Dig Dis Sci* 2000;45:1944-1948.
175. Ryder S, Koskinas J, Rizzi PM, McFarlane IG, Portmann BC, Naoumov NV, Williams R. Hepatocellular carcinoma complicating autoimmune hepatitis: role of hepatitis C virus. *HEPATOLOGY* 1995;22:718-722.
176. Liberman UA, Weiss SR, Broll J, Minne HW, Quan H, Bell NH, Rodriguez-Portales J, et al. Effect of oral alendronate on bone mineral density and the incidence of fractures in postmenopausal osteoporosis. *N Engl J Med* 1995;333:1437-1443.
177. Guanabens N, Pares A, Monegal A, Peris P, Pons F, Alvarez L, Martinez de Osaba MJ, et al. Etidronate versus fluoride for treatment of osteopenia in primary biliary cirrhosis: preliminary results after 2 years. *Gastroenterology* 1997;113:219-224.
178. Wolfhagen FHJ, van Buuren HR, den Ouden JW, Hop WCJ, van Leeuwen JPTM, Schalm SW, Pols HAP. Cyclical etidronate in the prevention of bone loss in corticosteroid-treated primary biliary cirrhosis. A prospective, controlled pilot study. *J Hepatol* 1997;26:325-330.
179. Yachha SK, Srivastava A, Chetri K, Saraswat VA, Krishnani N. Autoimmune liver disease in children. *J Gastroenterol Hepatol* 2001;16:674-677.
180. Debray D, Maggiore G, Girardet JP, Mallet E, Bernard O. Efficacy of cyclosporin A in children with type 2 autoimmune hepatitis. *J Pediatrics* 1999;135:111-114.
181. Alvarez F, Ciocca M, Canero-Velasco C, Ramonet M, de Davila MT, Cuarterolo M, Gonzalez T, et al. Short-term cyclosporine induces a remission of autoimmune hepatitis in children. *J Hepatol* 1999;30:222-227.
182. Malekzadeh R, Nasser-Moghaddam S, Kaviani M-J, Taheri H, Kamalian N, Sotoudeh M. Cyclosporin A is a promising alternative to corticosteroids in autoimmune hepatitis. *Dig Dis Sci* 2001;46:1321-1327.
183. Czaja AJ, Beaver SJ, Shiels MT. Sustained remission following corticosteroid therapy of severe HBsAg-negative chronic active hepatitis. *Gastroenterology* 1987;92:215-219.
184. Czaja AJ, Menon KVN, Carpenter HA. Sustained remission after corticosteroid therapy of type 1 autoimmune hepatitis: a retrospective analysis. *HEPATOLOGY* 2002;35:890-897.
185. Czaja AJ, Rakela J, Ludwig J. Features reflective of early prognosis in corticosteroid-treated severe autoimmune chronic active hepatitis. *Gastroenterology* 1988;95:448-453.
186. Czaja AJ, Ammon HV, Summerskill WHJ. Clinical features and prognosis of severe chronic active liver disease (CALD) after corticosteroid-induced remission. *Gastroenterology* 1980;78:518-523.
187. Czaja AJ, Ludwig J, Baggenstoss AH, Wolf A. Corticosteroid-treated chronic active hepatitis in remission. Uncertain prognosis of chronic persistent hepatitis. *N Engl J Med* 1981;304:5-9.
188. Hegarty JE, Nouri-Aria KT, Portmann B, Eddleston ALWF, Williams R. Relapse following treatment withdrawal in patients with autoimmune chronic active hepatitis. *HEPATOLOGY* 1983;3:685-689.
189. Schalm SW, Ammon HV, Summerskill WHJ. Failure of customary treatment in chronic active liver disease: causes and management. *Ann Clin Res* 1976;8:221-227.
190. Davis GL, Czaja AJ. Immediate and long-term results of corticosteroid therapy for severe idiopathic chronic active hepatitis. In: Czaja AJ, Dickson ER, eds. *Chronic Active Hepatitis. The Mayo Clinic Experience*. New York: Marcel Dekker, Inc., 1986:269-283.
191. Czaja AJ. Low dose corticosteroid therapy after multiple relapses of severe HBsAg-negative chronic active hepatitis. *HEPATOLOGY* 1990;11:1044-1049.
192. Runyon BA. Exquisite sensitivity to small decrements in corticosteroid dose in autoimmune chronic active hepatitis. *J Clin Gastroenterol* 1987; 9:541-542.
193. Stellan AJ, Keating JJ, Johnson PJ, MacFarlane IG, Williams R. Maintenance of remission in autoimmune chronic active hepatitis with azathioprine after corticosteroid withdrawal. *HEPATOLOGY* 1988; 8:781-784.
194. Johnson PJ, McFarlane IG, Williams R. Azathioprine for long-term maintenance of remission in autoimmune hepatitis. *N Engl J Med* 1995; 333:958-963.
195. Czaja AJ, Wang KK, Shiels MT, Katzmann JA. Oral pulse prednisone therapy after relapse of severe autoimmune chronic active hepatitis. A prospective randomized treatment trial evaluating clinical, biochemical, and lymphocyte subset responses. *J Hepatol* 1993;17:180-186.
196. Czaja AJ, Carpenter HA, Lindor KD. Ursodeoxycholic acid as adjunctive therapy for problematic type 1 autoimmune hepatitis: a randomized placebo-controlled treatment trial. *HEPATOLOGY* 1999;30:1381-1386.
197. Czaja AJ, Lindor KD. Failure of budesonide in a pilot study of treatment-dependent autoimmune hepatitis. *Gastroenterology* 2000;119:1312-1316.
198. Mistilis SP, Vickers CR, Darroch MH, McCarthy SW. Cyclosporin, a new treatment for autoimmune chronic active hepatitis. *Med J Austr* 1985;143:463-465.
199. Hyams JS, Ballou M, Leichtner AM. Cyclosporine treatment of autoimmune chronic active hepatitis. *Gastroenterology* 1987;93:890-893.
200. Person JL, McHutchison JG, Fong T-L, Redeker RG. A case of cyclosporine-sensitive, steroid-resistant, autoimmune chronic active hepatitis. *J Clin Gastroenterol* 1993;17:317-320.
201. Sherman KE, Narkewicz M, Pinto PC. Cyclosporine in the management of corticosteroid-resistant type 1 autoimmune chronic active hepatitis. *J Hepatol* 1994;21:1040-1047.
202. Jackson LD, Song E. Cyclosporin in the treatment of corticosteroid resistant autoimmune chronic active hepatitis. *Gut* 1995;36:459-461.
203. Fernandes NF, Redeker AG, Vierling JM, Villamil FG, Fong TL. Cyclosporine therapy in patients with steroid resistant autoimmune hepatitis. *Am J Gastroenterol* 1999;94:241-248.
204. Pratt DS, Flavin DP, Kaplan MM. The successful treatment of autoimmune hepatitis with 6-mercaptopurine after failure with azathioprine. *Gastroenterology* 1996;110:271-274.
205. Burak KW, Urbanski SJ, Swain MG. Successful treatment of refractory type 1 autoimmune hepatitis with methotrexate. *J Hepatol* 1998;29:990-993.
206. Kanzler S, Gerken G, Dienes HP, Meyer zum Buschenfelde KH, Lohse AW. Cyclophosphamide as alternative immunosuppressive therapy for autoimmune hepatitis—report of three cases. *Z Gastroenterol* 1997;35: 571-578.
207. Richardson PD, James PD, Ryder SD. Mycophenolate mofetil for maintenance of remission in autoimmune hepatitis patients resistant to or intolerant of azathioprine. *J Hepatol* 2000;33:371-375.
208. Seaberg EC, Belle SH, Beringer KC, Schivins JL, Detre KM. Liver transplantation in the United States from 1987-1998: updated results from the Pitt-UNOS liver transplant registry. In: Cecka JM, Terasaki PI, eds. *Clinical Transplants 1998*. Los Angeles: UCLA Tissue Typing Laboratories 1999:17-37.
209. Hurtova M, Duclos-Vallee J-C, Johanet C, Emile J-F, Roque-Afonso A-M, Feray C, Bismuth H, et al. Successful tacrolimus therapy for severe recurrence of type 1 autoimmune hepatitis in a liver graft recipient. *Liver Transpl* 2001;7:556-558.
210. Jones DEJ, James OFW, Portmann B, Burt AD, Williams R, Hudson M. Development of autoimmune hepatitis following liver transplantation for primary biliary cirrhosis. *HEPATOLOGY* 1999;30:53-57.
211. Heneghan MA, Portmann BC, Norris SM, Williams R, Muiesan P, Rela M, Heaton ND, O'Grady JG. Graft dysfunction mimicking autoim-

- immune hepatitis following liver transplantation in adults. *HEPATOLOGY* 2001;34:464-470.
212. Kerkar N, Hadzic N, Davies ET, Portmann B, Donaldson PT, Rela M, Heaton ND, et al. De-novo autoimmune hepatitis after liver transplantation. *Lancet* 1998;353:409-413.
213. Spada M, Bertani A, Sonzogni A, Petz W, Riva S, Torre G, Melzi ML, et al. A cause of late graft dysfunction after liver transplantation in children: de-novo autoimmune hepatitis. *Transplantation Proc* 2001;33:1747-1748.
214. Gupta P, Hart J, Millis JM, Cronin D, Brady L. De novo hepatitis with autoimmune antibodies and atypical histology. A rare cause of late graft dysfunction after pediatric liver transplantation. *Transplantation* 2001;71:664-668.
215. Salcedo M, Vaquero J, Banares R, Rodriguez-Mahou M, Alvarez E, Vicario JL, Hernandez-Albujar A, et al. Response to steroids in de novo autoimmune hepatitis after transplantation. *HEPATOLOGY* 2002;35:349-356.
216. Czaja AJ. Autoimmune hepatitis after liver transplantation and other lessons of self intolerance. *Liver Transplantation* 2002;8:505-513.